

# Encephalitis

Encephalitis

encephalitisjournal.org

Vol 1 · No 1 · January 2021

Encephalitis

Vol 1 · No 1 · January 2021

Vol 1 · No 1 · January 2021



Symptomatic treatments of *N*-methyl-D-aspartate receptor encephalitis

Soon-Tae Lee

Initial cerebrospinal fluid-restricted oligoclonal bands associate with anti-*N*-methyl-D-aspartate receptor encephalitis severity: a pilot study

Sang Bin Hong, Yong-Won Shin, Jangsup Moon, Woo-Jin Lee, Kon Chu, Sang Kun Lee

Korean Encephalitis and Neuroinflammation Society

## Aims and Scope

*Encephalitis* is a peer-reviewed, Open Access journal that publishes original research articles, review/mini-review articles, and experimental or clinical studies/case reports on encephalitis and neuroinflammation. The journal was launched in January 2021 and is published quarterly on the 10th of every January, April, July, and October.

Encephalitis is a disease caused by the neuroinflammation in the brain. Neuroinflammation refers to inflammation that occurs in the nerves system. It can be triggered by a variety of causes or events, including infection, traumatic brain injury, seizure, toxic metabolites, and autoimmune responses. Acute inflammation is characterized by transient changes in inflammatory molecules, endothelial cell activation, and platelet deposition, but chronic inflammation is involved in the prolonged activation of glial cells and recruitment of other immune cells into the brain. The symptoms of encephalitis include severe headache, fever, confusion, seizures, trouble speaking, and memory problems. Although viral infections are considered the most common cause of encephalitis, in many cases the cause remains unknown, although it can be life-threatening. It is important to get a timely diagnosis and treatment.

Priority of *Encephalitis* is given to work that provides translational and/or fundamental insight into the workings of encephalitis and neuro-immune interactions in the brain. covers a wide range of topics related to encephalitis/neuroinflammation including neuroscience, immunology, pathophysiology, pharmacology, microbiology, genomics, diagnosis, cure of infectious diseases, and related general experimental and clinical research on the nervous system. *Encephalitis* serves as the major conduit of top-quality information for neuroscientist or neurobiologist community, as well as the neurologist community.

Acceptance for publication of submitted manuscript is determined by the editors and peer reviewers, who are experts in their specific fields of each topic. Review processing is performed by the editorial board members of journal and outside experts. All published articles will be assigned DOI provided by CrossRef.

## Open Access

This is an Open Access journal distributed under the terms of the Creative Commons Attribution Non-Commercial License (<http://creativecommons.org/licenses/by-nc/4.0/>) which permits unrestricted non-commercial use, distribution, and reproduction in any medium, provided the original work is properly cited.

---

### Publisher

Manho Kim, Seoul National University, Korea

### Editor-in-Chief

Kyung-Il Park, Seoul National University Hospital, Seoul, Korea

### Editorial Office

Korean Encephalitis and Neuroinflammation Society

101 Daehak-ro, Jongno-gu, Seoul 03080, Korea

Tel: +82-2-2072-0629 Fax: +82-2-765-7920 E-mail: [encephalitis.office@kens.or.kr](mailto:encephalitis.office@kens.or.kr)

### Printing Office

M2PI

8th FL, DreamTower, 66 Seongsui-ro, Seongdong-gu, Seoul 04784, Korea

Tel: +82-2-2190-7300 Fax: +82-2-2190-7333 E-mail: [journal@m2community.co.kr](mailto:journal@m2community.co.kr)

Published on January 10, 2021

Copyright © 2021 Korean Encephalitis and Neuroinflammation Society

Ⓢ This paper meets the requirements of KS X ISO 9706, ISO 9706-1994 and ANSI/NISO Z39. 48-1992 (Permanence of paper)

### Editor-in-Chief

Kyung-Il Park *Department of Neurology, Seoul National University Hospital Healthcare System Gangnam Center, Korea*

### Associate Editors

Daejong Jeon *Advanced Neural Technologies, Korea*

Jangsup Moon *Department of Neurology, Rare Disease Center, Seoul National University Hospital, Korea*

### Editorial Board

Kon Chu *Department of Neurology, Seoul National University Hospital, Korea*

Keun-Hwa Jung *Department of Neurology, Seoul National University Hospital, Korea*

Kwang Ki Kim *Department of Neurology, Dongguk University Ilsan Hospital, Korea*

Yong Seo Koo *Department of Neurology, Asan Medical Center, Korea*

Sang Kun Lee *Department of Neurology, Seoul National University Hospital, Korea*

Soon-Tae Lee *Department of Neurology, Seoul National University Hospital, Korea*

Byung Chan Lim *Department of Pediatrics, Seoul National University Children's Hospital, Korea*

### English Editor

Eworld Editing *Korea*

### Manuscript Editor

Yoon Joo Seo *InfoLumi, Korea*

### Layout Editor

In A Park *M2PI, Korea*

### Website and JATS XML File Producer

Min Young Choi *M2PI, Korea*

Vol 1 · No 1 · January 2021

### Editorial

- 1** Congratulatory remarks on expanding the research field for encephalitis and neuroinflammation  
Sang Kun Lee
- 2** New era exploring the brain  
Manho Kim
- 3** With a new journal "*Encephalitis*," hope to feel inspired  
Kyung-Il Park

### Review Article


- 4** Symptomatic treatments of *N*-methyl-D-aspartate receptor encephalitis  
Soon-Tae Lee

### Original Articles

- 7** Initial cerebrospinal fluid-restricted oligoclonal bands associate with anti-*N*-methyl-D-aspartate receptor encephalitis severity: a pilot study  
Sang Bin Hong, Yong-Won Shin, Jangsup Moon, Woo-Jin Lee, Kon Chu, Sang Kun Lee
- 14** Respiratory virus-related meningoencephalitis in adults  
Seon-Jae Ahn, Jangsup Moon, Jun-Sang Sunwoo, Jin-Sun Jun, Soon-Tae Lee, Kyung-Il Park, Keun-Hwa Jung, Ki-Young Jung, Manho Kim, Sang Kun Lee, Kon Chu

### Case Reports

- 20** Refractory neuro-Sweet disease successfully treated with tocilizumab and mycophenolate mofetil  
Sungeun Hwang, Hyoshin Son, Jangsup Moon, Soon-Tae Lee, Keun Hwa Jung, Kyung-Il Park, Sang Kun Lee, Kon Chu
- 25** Anti-*N*-methyl-D-aspartate receptor encephalitis 8 years after serial herpes simplex virus type 1 and human herpesvirus type 7 encephalitis  
Yoonhyuk Jang, Jeong-Min Kim, Jangsup Moon, Kyung-Il Park, Soon-Tae Lee, Keun-Hwa Jung, Sang Kun Lee, Kon Chu



## Congratulatory remarks on expanding the research field for encephalitis and neuroinflammation

Sang Kun Lee

*Department of Neurology, Laboratory for Neurotherapeutics, Comprehensive Epilepsy Center, Seoul National University Hospital, Seoul, Korea*

On behalf of all members of our society, it is my great pleasure and privilege to congratulate the publication of the first issue of *Encephalitis*. The field of encephalitis and neuroinflammation is an extraordinary field of neuroscience that gives us a sense of awe. It includes various kinds of encephalitis and altered neuroimmunology diseases with remarkable clinical characteristics, which gives us very important insights into neuroscience regardless of the basic and clinical aspects.

Recently, many new categories of encephalitis have been found and the efforts to discover novel forms of this disease are also ongoing. With these discoveries and their associated efforts, we can begin to grasp the secrets of neuroimmunology and the functions and the connections between various neural systems macroscopically and microscopically. We, therefore, are able to refine the diagnosis and treatment of various encephalitis and neuroinflammation diseases and step forward to save the lives of patients and nervous system function.

Many more studies should provide us with a greater under-

standing of the mechanisms of these diseases and aid in further treatment strategy developments at the state of the art level. Korea is one of the leading countries doing cutting edge research to develop diagnosis and treatment guidelines for encephalitis diseases. As a result, we need a more suitable vehicle such as *Encephalitis* to reach these various goals. *Encephalitis* is dedicated to original research that encompasses basic and clinical fields that investigate encephalitis, neuroinflammation, and neuroimmunology. Case reports are also welcome. All the members of the Editorial Board and publication staff are looking forward to receiving a wide range of submissions and contributions from all international researchers and clinicians. Thank you very much.

Warm regards,

Sang Kun Lee

Honorary President,  
Korean Encephalitis and Neuroinflammation Society

Received: December 28, 2020 Accepted: December 31, 2020

Correspondence: Sang Kun Lee

Department of Neurology, Laboratory for Neurotherapeutics, Comprehensive Epilepsy Center, Seoul National University Hospital, 101 Daehak-ro, Jongno-gu, Seoul 03080, Korea

E-mail: [sangkun2923@gmail.com](mailto:sangkun2923@gmail.com)

ORCID: <https://orcid.org/0000-0003-1908-0699>

Copyright © 2021 by The Korean Encephalitis and Neuroinflammation Society

This is an open access article distributed under the terms of the Creative Commons Attribution Non-Commercial License (<http://creativecommons.org/licenses/by-nc/4.0/>) which permits unrestricted non-commercial use, distribution, and reproduction in any medium, provided the original work is properly cited.



## New era exploring the brain

Manho Kim

*Department of Neurology, Seoul National University Hospital, Seoul National University College of Medicine, Seoul, Korea*

*Encephalitis* is the first official journal of the Korean Encephalitis and Neuroinflammation Society (KENS) which was established in September, 2013.

With delight and deep appreciation, I extend special thanks to all the staff who have spent time and effort to launch the journal, expecting it will be a leader in advanced neurology research.

Even a decade ago, as is the case for most neurologists, patients with encephalitis were regarded as a part of the infection, thus, many of them were managed according to a standard protocol, such as anti-viral agents with seizure or intracranial pressure controls. However, even with rigorous treatment, some patients did not survive or were left with severe neurological deficits. Even the causative agents were not known.

Since the discovery of autoimmune encephalitis, starting with anti-*N*-methyl-D-aspartate receptor encephalitis, experts at this institution developed and began to provide diagnosis guidelines

all across the country, along with consultations for clinical practitioners. Several thousand patients' lives were saved. Accumulating experiences have been communicated via lectures at seminars or conferences as well as among the members of KENS.

The discoveries so far are big steps in the exploration of the brain. Expanding datasets are expected and will need to be organized, from case reports to clinical trials, from basic and translational neuroscience to clinical practice, and then systematic reviews to update the new advances.

Now, as the second president of KENS, it is my great honor to celebrate launching the journal, *Encephalitis*.

With my best regards,

Manho Kim

President, Korean Encephalitis and Neuroinflammation Society

Received: December 28, 2020 Accepted: December 31, 2020

Correspondence: Manho Kim

Department of Neurology, Seoul National University Hospital, Seoul National University College of Medicine, 101 Daehak-ro, Jongno-gu, Seoul 03080, Korea

E-mail: kimmanho@snu.ac.kr

ORCID: <https://orcid.org/0000-0002-0277-6326>

Copyright © 2021 by The Korean Encephalitis and Neuroinflammation Society

This is an open access article distributed under the terms of the Creative Commons Attribution Non-Commercial License (<http://creativecommons.org/licenses/by-nc/4.0/>) which permits unrestricted non-commercial use, distribution, and reproduction in any medium, provided the original work is properly cited.



## With a new journal “*Encephalitis*,” hope to feel inspired

Kyung-Il Park<sup>1,2</sup>

<sup>1</sup>Department of Neurology, Seoul National University Hospital, Seoul, Korea

<sup>2</sup>Department of Neurology, Seoul National University Hospital Healthcare System Gangnam Center, Seoul, Korea

Dear colleagues,

It is our great pleasure to announce a new journal, “*Encephalitis*,” and to share this news with all neurologists and neuroscientists. Moreover, my opportunity to serve as the founding editor-in-chief for this journal is a great honor and I appreciate the Korean Encephalitis and Neuroinflammation Society for appointing me to this position.

This journal is born from two continuing streams of academic study. The first one is neuroinflammation and the other is encephalitis. For a few decades, central nervous system (CNS) immunology was regarded as one of the common mechanisms of neurological diseases including acute as well as chronic degenerative diseases. Since researchers’ long-held belief was that inflammatory responses could be controlled easily, they focused on neuroinflammation in nearly all kinds of neurologic diseases. However, excluding a few diseases such as multiple sclerosis and other some immunologic CNS diseases, we have recognized that neuroinflammation is only a part of disease, and inflammatory reactions are complex and thus, carefully targeted treatment is warranted. Encephalitis is a challenging disease for all neurologists. The first decision is whether the disease is infectious or noninfectious, which though it looks like an easy distinction, is definitely not that easy. The potential hope has been that the diagnostic yields for infectious organisms have been

improved by novel technologies. However, in cases when non-infectious etiologies are suspected, diagnosis is a bumpy ride. Recent discovery of numerous autoantibodies and methods to detect these could help classify diseases more clearly and improve clinical outcomes, which deepen our knowledge of neuroimmunology.

Since the birth of the Korean Encephalitis and Neuroinflammation Society in 2013, core members in this society have put a lot of effort into uncovering the evidence for encephalitis and neuroinflammation that is relevant to diagnosis and treatment. Personally, I hope both basic researchers and clinicians who investigate encephalitis and neuroinflammation will actively submit articles and serve in the peer-review process. Novel basic or translational trials are welcomed, even if negative results are obtained. According to our aims and scope, this journal does not restrict articles on encephalitis but, can accept a broad range of all neuroinflammatory studies, which reveal the roles of inflammation in general neurological diseases. I look forward to meeting you as authors, reviewers, and readers in this journal soon.

With best regards,

Kyung-Il Park

Editor-in-chief, *Encephalitis*

Received: December 28, 2020 Accepted: December 31, 2020

Correspondence: Kyung-Il Park

Department of Neurology, Seoul National University Hospital Healthcare System Gangnam Center, Gangnam Finance Center, 152 Teheran-ro, Gangnam-gu, Seoul 06236, Korea

E-mail: [ideopki@gmail.com](mailto:ideopki@gmail.com)

ORCID: <https://orcid.org/0000-0001-8064-6749>

Copyright © 2021 by The Korean Encephalitis and Neuroinflammation Society

This is an open access article distributed under the terms of the Creative Commons Attribution Non-Commercial License (<http://creativecommons.org/licenses/by-nc/4.0/>) which permits unrestricted non-commercial use, distribution, and reproduction in any medium, provided the original work is properly cited.

## Symptomatic treatments of *N*-methyl-D-aspartate receptor encephalitis

Soon-Tae Lee

Department of Neurology, Seoul National University Hospital, Seoul, Korea

*N*-methyl-D-aspartate receptor (NMDAR) encephalitis presents with multiple symptoms including memory loss, seizure, psychosis, aphasia, altered mentality, dyskinesia, autonomic dysfunction, and central hypoventilation. While immunotherapy protocols are improving, morbidity and mortality in the disease largely depend on supportive care to control intractable symptoms. However, no prospective or controlled trials have been conducted on immunotherapy or supportive care principles in the disease. Thus, this study discusses and shares experience and ideas for symptomatic care of NMDAR encephalitis.

**Keywords:** *N*-methyl-D-aspartate receptor, Encephalitis, Symptomatic, Treatment

### Introduction

*N*-methyl-D-aspartate receptor (NMDAR) encephalitis is the most common and serious form of autoimmune encephalitis. It is caused by autoantibody against NR1 subunit of the NMDAR receptor. Key symptoms include memory loss, psychosis, seizure, aphasia, altered mentality, dyskinesia, autonomic dysfunction, and central hypoventilation [1]. Immunotherapy is the main treatment and includes steroid, immunoglobulin, rituximab, tocilizumab, and/or cyclophosphamide, which are frequently combined to enhance outcomes. Although the final outcome has been improved after the application of novel immunotherapies, there still exist a lot of mortality and permanent morbidity by the disease. When treated for up to 24 months, 25% of patients remained disabled in 3 to 6 categories of the modified Rankin Score [1]. Hence, long-term integrated supportive care is essential until the full effect of immunotherapy can ameliorate disease symptoms.

This paper summarizes the details of supportive care for disabling symptoms of NMDAR encephalitis based on reported evidences and personal experience.

### Memory Loss

Because NMDAR mediates long-term potentiation of memory [2], memory loss is the early and key symptom in NMDAR encephalitis. However, currently no symptomatic treatment is available to enhance memory function in this disease. EphB2 receptors form a complex with NMDAR, and anti-NMDAR antibodies disrupt the cross-talk between NMDAR and EphB2 receptors [3]. Moreover, ephrin-B2 (the ligand of the EphB2 receptor) prevents intracellular internalization of NMDAR by disease antibodies [4]. Accordingly, some chemicals modulating the EphB2 receptor could affect NMDAR encephalitis symptoms; however, no clinically usable drugs have been approved for this purpose. Because memory loss is largely reversible after remission of the disease, education regarding the disease course and psychological support for family members are necessary.

### Psychosis

Psychosis and behavioral problems not only increase caregiver burden but also can result in self-injury. To control psychosis, antipsychotics such as dopaminergic blockers and anxiolytics

Received: November 4, 2020 Revised: November 30, 2020 Accepted: December 1, 2020

Correspondence: Soon-Tae Lee

Department of Neurology, Seoul National University Hospital, 101 Daehak-ro, Jongno-gu, Seoul 03080, Korea

E-mail: staelee@snu.ac.kr

ORCID: <https://orcid.org/0000-0003-4767-7564>

Copyright © 2021 by The Korean Encephalitis and Neuroinflammation Society

This is an open access article distributed under the terms of the Creative Commons Attribution Non-Commercial License (<http://creativecommons.org/licenses/by-nc/4.0/>) which permits unrestricted non-commercial use, distribution, and reproduction in any medium, provided the original work is properly cited.



such as benzodiazepine can be prescribed. Because the pattern of psychosis is variable [5], control of symptoms depends on individual phenotypes. While psychiatric symptoms that emerge in the early disease phase can be partially controlled by antipsychotics, close monitoring is necessary because antipsychotics can aggravate rhabdomyolysis or induce neuroleptic malignant syndrome, especially in patients with dyskinesia [6]. Atypical antipsychotics can reduce extrapyramidal side effects, although further studies are needed. Similar to other symptoms of the disease, immunotherapy is the main tool to control psychosis. Meanwhile, psychosis is often re-aggravated during the later stages of the disease, and re-introduction of antipsychotics is sometimes necessary. Hyperactive forms of psychosis can re-emerge, such as anxiety, anger, or disinhibition, usually accompanied by improvements in memory function.

## Dyskinesia

Dyskinesia is one of the most troublesome symptoms of the disease. Down-regulated NMDAR expression causes dopaminergic overactivation in the globus pallidus and might cause hyperkinetic movement disorders [7]. Severe dyskinesia causes self-injury, rhabdomyolysis, and renal failure [6]. In intensive care units, anesthetics or neuromuscular blockers are necessary in severe cases. However, when dyskinesia continues for several months, prolonged use of these agents is not clinically feasible due to other systemic complications.

Recently, I have shown that mega-dose enteral diazepam (ranging from 6 to 180 mg) can control dyskinesia effectively [8]. Previously, diazepam has demonstrated muscle-relaxant properties in neuroleptic malignant syndrome and tetanus [9,10]. In the severe form of dyskinesia resulting from NMDAR encephalitis, mega-dose diazepam decreased the severity of dyskinesia to tolerable levels and no patients had serious adverse events except mild sedation [8]. By using mega-dose diazepam, I could stop anesthetics or neuromuscular blockers in many patients and the effect was durable for the remaining immunotherapy period. I usually start diazepam at a medium dose (3–5 mg, three or four times daily) and then double the dose every several days depending on response, up to a maximum of 180 mg daily. Mega-dose enteral diazepam could be an effective treatment option for controlling dyskinesia in NMDAR encephalitis.

## Seizure

The management of epilepsy in NMDAR encephalitis is in line with the management of autoimmune epilepsy, the clinical ap-

proach of which is described in a previous consensus [11]. In terms of antiepileptic drug (AED) selection, selection depends on clinician preference, seizure semiology, related medical conditions, and side effect profiles. Drugs with fewer side effects, no drug-drug interactions and that are fast loading are preferred, and next-generation AEDs such as levetiracetam, lacosamide, perampanel, zonisamide, topiramate, and pregabalin are good candidates for first-line use. However, because levetiracetam and perampanel can aggravate psychosis, they are frequently replaced with other AEDs when used in NMDAR encephalitis with psychiatric symptoms. Topiramate can cause language problems and memory decline, and its use is sometimes terminated early in NMDAR patients with language dysfunction and memory loss. Patients with aggressive immunotherapy often show neutropenia, which could be a side effect of immunotherapy or a hematologic side effect of AED. In patients being treated with steroid or cyclophosphamide, enzyme-inducing AEDs, such as phenytoin, phenobarbital, and carbamazepine, increase the hepatic degradation of the immunotherapy drugs, dampening the pharmacokinetics. Accordingly, non-enzyme-inducing AEDs are recommended for use in combination with immunotherapeutic agents with hepatic metabolism.

## Hypersalivation

Hypersalivation is one of the symptoms caused by autonomic dysfunction in NMDAR encephalitis with a prevalence of 4% to 18% [12]. Hypersalivation is associated with profound drooling, constant suction, pneumonia, and sometimes volume depletion. While anticholinergics are often tried in other diseases, they can aggravate autonomic dysfunction and paralytic ileus in NMDAR encephalitis. Accordingly, effective treatments without systemic side effects are needed.

My team has shown that botulinum toxin injection into the salivary glands can control hypersalivation in NMDAR encephalitis [13]. The effects of one injection last for 12 to 16 weeks and sufficient mitigate the need for other anticholinergics. The injection can be repeated if needed after 12 weeks. Botulinum toxin is a better choice than anticholinergics for management of hypersalivation in NMDAR encephalitis.

## Autonomic dysfunction

Autonomic dysfunction causes fluctuation in blood pressure and heart rate in NMDAR encephalitis. In severe cases, hypotension can cause ischemic organ damage such as ischemic hepatitis. Some patients show sinus arrest, the mechanism for

which is not fully understood, and need temporary pacemakers. To minimize complications of autonomic dysfunction, anticholinergic drugs should be prescribed with caution. Cholinergic drugs such as pyridostigmine can be helpful, and I frequently prescribe them in patients with paralytic ileus. However, they can increase salivation, and the overall clinical efficacy should be determined in further controlled trials. Midodrine can help to correct hypotension. Blood pressure and heart rate are very sensitive to beta-blockers, and these drugs should be used with caution because they can cause hypotension or bradycardia even at low doses.

## Hypoventilation

Central hypoventilation in NMDAR encephalitis is the main cause of mortality and morbidity via hypoxic brain damage in general wards. If a patient shows rapid progression of the disease, especially altered mentality and dyskinesia, monitoring of oxygen saturation and heart rhythm might be helpful to detect central hypoventilation. Once it occurs, hypoventilation means that the disease course is severe and that 1-year outcomes will be poor, as indicated by the anti-NMDAR Encephalitis One-Year Functional Status (NEOS) score [14]. Intubation, tracheostomy, and ventilator care are inevitable in most patients with central hypoventilation.

## Conclusion

Immunotherapy is the main treatment of NMDAR encephalitis and improves symptoms of the disease. Nevertheless, supportive care is needed to decrease mortality and morbidity. While the protocol for immunotherapy improves every year and several controlled trials on NMDAR encephalitis are being initiated, prospective research is also needed on supportive care topics. Because the final immunologic prognosis of NMDAR encephalitis is usually excellent, the management of organ damage and complications during the disease course is important to prevent permanent physical sequelae of this disease.

## Conflicts of Interest

Soon-Tae Lee has been editorial board of *Encephalitis* since October 2020. He was not involved in the review process of this review article.

Soon-Tae Lee have an advisory role for Genentech, UCB, and Ono Pharmaceuticals outside of the current work, and received

research grants from GC Pharma outside of the current work.

## References

1. Lee WJ, Lee ST, Shin YW, et al. Teratoma Removal, Steroid, IVIG, Rituximab and Tocilizumab (T-SIRT) in anti-NMDAR encephalitis. *Neurotherapeutics* 2020 Sep 3 [Epub]. <https://doi.org/10.1007/s13311-020-00921-7>.
2. Lipton SA. Paradigm shift in neuroprotection by NMDA receptor blockade: memantine and beyond. *Nat Rev Drug Discov* 2006;5:160–170.
3. Mikasova L, De Rossi P, Bouchet D, et al. Disrupted surface cross-talk between NMDA and Ephrin-B2 receptors in anti-NMDA encephalitis. *Brain* 2012;135(Pt 5):1606–1621.
4. Planagumà J, Haselmann H, Mannara F, et al. Ephrin-B2 prevents N-methyl-D-aspartate receptor antibody effects on memory and neuroplasticity. *Ann Neurol* 2016;80:388–400.
5. Al-Diwani A, Handel A, Townsend L, et al. The psychopathology of NMDAR-antibody encephalitis in adults: a systematic review and phenotypic analysis of individual patient data. *Lancet Psychiatry* 2019;6:235–246.
6. Lim JA, Lee ST, Kim TJ, et al. Frequent rhabdomyolysis in anti-NMDA receptor encephalitis. *J Neuroimmunol* 2016;298:178–180.
7. Masdeu JC, Dalmau J, Berman KF. NMDA receptor internalization by autoantibodies: a reversible mechanism underlying psychosis? *Trends Neurosci* 2016;39:300–310.
8. Shin HR, Jang Y, Shin YW, Chu K, Lee SK, Lee ST. High-dose diazepam controls severe dyskinesia in Anti-NMDA receptor encephalitis. *Neurol Clin Pract* 2020 Nov 2 [Epub]. <https://doi.org/10.1212/CPJ.0000000000001001>.
9. Kontaxakis VP, Christodoulou GN, Markidis MP, Havaki-Kontaxaki BJ. Treatment of a mild form of neuroleptic malignant syndrome with oral diazepam. *Acta Psychiatr Scand* 1988;78:396–398.
10. Okoromah CN, Lesi FE. Diazepam for treating tetanus. *Cochrane Database Syst Rev* 2004;(1):CD003954.
11. Jang Y, Kim DW, Yang KI, et al. Clinical approach to autoimmune epilepsy. *J Clin Neurol* 2020;16:519–529.
12. Dalmau J, Gleichman AJ, Hughes EG, et al. Anti-NMDA-receptor encephalitis: case series and analysis of the effects of antibodies. *Lancet Neurol* 2008;7:1091–1098.
13. Jun JS, Seo HG, Lee ST, Chu K, Lee SK. Botulinum toxin treatment for hypersalivation in anti-NMDA receptor encephalitis. *Ann Clin Transl Neurol* 2017;4:830–834.
14. Balu R, McCracken L, Lancaster E, Graus F, Dalmau J, Titulaer MJ. A score that predicts 1-year functional status in patients with anti-NMDA receptor encephalitis. *Neurology* 2019;92:e244–e252.

## Initial cerebrospinal fluid-restricted oligoclonal bands associate with anti-*N*-methyl-D-aspartate receptor encephalitis severity: a pilot study

Sang Bin Hong<sup>1</sup>, Yong-Won Shin<sup>2</sup>, Jangsup Moon<sup>3</sup>, Woo-Jin Lee<sup>1</sup>, Kon Chu<sup>1</sup>, Sang Kun Lee<sup>1</sup>

<sup>1</sup>Department of Neurology, Seoul National University Hospital, Seoul, Korea

<sup>2</sup>Department of Neurosurgery, Center for Hospital Medicine, Seoul National University Hospital, Seoul, Korea

<sup>3</sup>Rare Disease Center, Seoul National University Hospital, Seoul, Korea

### Purpose

Intrathecal antibody production is thought to underly the pathogenesis and symptomatology of *N*-methyl-D-aspartate receptor encephalitis (NMDARE). In the present study, the clinical correlation of cerebrospinal fluid (CSF) restricted oligoclonal bands (OCBs), as a measure of intrathecal antibody synthesis, was examined in confirmed NMDARE cases.

### Methods

The present study included patients with a confirmed diagnosis of NMDARE who underwent initial CSF evaluation and were followed up for a minimum of 12 months. Disease severity was assessed at baseline and 1, 3, 6, 9, and 12 months. Data regarding duration of hospitalization and intensive care unit (ICU) stay, the presence of uncontrolled seizures, and antiepileptic drug requirement were obtained for each patient.

### Results

Among the 14 confirmed NMDARE patients, seven had CSF-OCBs. The presence of CSF-OCBs was associated with a more severe disease at baseline ( $p = 0.004$ ), worse final outcome ( $p = 0.005$ ), and longer hospitalization (median, 19 vs. 173 days;  $p < 0.001$ ) and ICU stay (median, 0 vs. 29 days;  $p = 0.006$ ). CSF-OCB positivity was closely associated with treatment refractoriness within 4 weeks ( $p = 0.029$ ).

### Conclusion

The presence of CSF-OCBs at the onset of disease in NMDARE patients was associated with initial treatment refractoriness and a more severe disease course leading to longer hospitalization, ICU admission, intractable seizures, and a poorer outcome. The results indicate that CSF-OCBs may be useful for prognostication. Furthermore, severe disease in NMDARE may be accompanied by oligoclonal expansion antibody-producing B cells.

**Keywords:** Autoimmune limbic encephalitis, Oligoclonal bands, Anti-*N*-methyl-D-aspartate receptor encephalitis

## Introduction

With the increasing availability of antibody assays and clinical awareness of autoimmune encephalitides as a diagnosis of encephalitis, a growing literature exists on the diverse range of clinical manifestations of autoimmune encephalitides. One of

the most commonly identified autoimmune encephalitis is anti-*N*-methyl-D-aspartate receptor encephalitis (NMDARE). NMDARE symptoms can range from seemingly benign to life-threatening [1-4]. Reliable biomarkers predictive of disease course at symptom onset would facilitate the administration of

Received: November 2, 2020 Accepted: October 9, 2020

Correspondence: Kon Chu

Department of Neurology, Seoul National University Hospital, 101 Daehak-ro, Jongno-gu, Seoul 03080, Korea

E-mail: stemcell.snu@gmail.com

ORCID: <https://orcid.org/0000-0001-5863-0302>

Copyright © 2021 by The Korean Encephalitis and Neuroinflammation Society

This is an open access article distributed under the terms of the Creative Commons Attribution Non-Commercial License (<http://creativecommons.org/licenses/by-nc/4.0/>) which permits unrestricted non-commercial use, distribution, and reproduction in any medium, provided the original work is properly cited.

timely immunotherapy and adequate medical management of complications.

Previous prognostication scores, such as the anti-NMDA Receptor Encephalitis One-Year Functional Status (NEOS) score [5], have utilized various indices of disease severity to predict functional outcome. The prognostic potential of various baseline variables, symptoms, and clinical assessments in NMDARE have been evaluated in other studies [6,7]. However, despite many efforts to determine factors associated with prognosis in NMDARE, a more reliable biomarker with fewer practical limitations is currently needed [8].

Prior research indicates the pathology in NMDARE is directly mediated by the intrathecal presence of anti-NMDA receptor (NMDAR) antibodies, leading to the possibility that patient cerebrospinal fluid (CSF) may provide relevant information for predicting disease severity. However, commonly tested CSF parameters such as leukocyte count or protein level inconsistently correlate with prognosis [9,10]. Other CSF tests such as anti-NMDAR antibody titers [11] have a more limited applicability in the clinical setting.

CSF-restricted oligoclonal bands (CSF-OCBs) are present in various immune-mediated neurologic disorders, such as multiple sclerosis (MS), and central nervous system (CNS) infections. In MS in particular, diagnostic and prognostic use of CSF-OCBs has long been established [12], with more than two or three CSF-OCBs signifying dissemination in time and portending a severe disease course with more frequent relapses. In the NMDARE setting, CSF-OCB, as a sensitive and standard measure of intrathecal antibody synthesis, may also reflect disease activity and prognosis associated with expansion of clonal intrathecal antibody production.

In the present study, the clinical correlation of the presence of CSF-OCBs was examined and its potential value as a prognostic biomarker in NMDARE evaluated.

## Methods

### Subjects

The present study included patients with a definite diagnosis of NMDARE according to the criteria previously published [13], and subjects who underwent initial CSF evaluation, including CSF-OCB testing at our hospital. The patients were followed up for a minimum of 12 months. Informed written consent was obtained from each patient or patient guardian, and the study was approved by the Institutional Review Board at Seoul National University Hospital (No. 1204-078-406).

### Diagnosis of anti-NMDARE

NMDARE was diagnosed based on clinical features, brain magnetic resonance imaging (MRI), CSF analysis, electroencephalography, and presence of anti-NMDAR antibodies in the CSF or serum. A commercial cell-based immunochemistry method and indirect fluorescence assay using human embryonic kidney 293 cells (Euroimmun AG, Lübeck, Germany) was used to screen for antibodies to NMDAR as previously described in the literature [14].

### OCB testing

The presence of CSF-OCBs was tested at initial presentation with CSF and paired serum sampling using gel electrophoresis and isoelectric focusing with immunofixation. Positive results included an oligoclonal response of more than two bands in the CSF with the paired serum showing a normal polyclonal response, and a CSF oligoclonal pattern of different isoelectric points compared with the serum. Negative results included a polyclonal response in both CSF and sera, a mirror type response with similar OCBs in CSF and sera, or a monoclonal response typical for paraproteins.

### Clinical outcomes

Modified Rankin Scale (mRS) and clinical assessment scale in autoimmune encephalitis (CASE), as previously detailed [15], were used to assess each patient at baseline, and 1, 3, 6, 9, and 12 months, and last follow-up time points. Information on the length of intensive care unit (ICU) stay and hospitalization was also collected. To estimate the severity of seizures, information on antiepileptic drug (AED) prescription and seizure control was obtained based on retrospective review of medical records.

For each patient, the NEOS score [5], a 5-point maximum score comprising ICU admission, treatment delay of > 4 weeks, lack of clinical response to treatment within 4 weeks, MRI abnormality, and elevated CSF leukocyte count > 20 cells, was calculated based on retrospective review of medical records. The relationship between NEOS score and OCB components was examined. The performance of the NEOS score and OCB predicting 12-month outcomes (mRS 0-1: no impairment, mRS 2-5: impairment) was compared.

### Statistical analyses

Statistical analyses were performed using R 3.6.1 (R Foundation for Statistical Computing, Vienna, Austria). Wilcoxon rank-sum test, Fisher exact test, and Spearman correlation test were used as appropriate. A p-value of < 0.05 was considered statistically significant.

**Table 1** Baseline characteristics of the study population

Characteristic	CSF-OCB-negative (n = 7)	CSF-OCB-positive (n = 7)	p-value
Age (yr)	24 (19–45)	27 (22–44)	0.95
Female sex	5 (71.4)	5 (71.4)	> 0.999
CSF sampling after IVIg treatment <sup>a</sup>	4 (57.1)	5 (71.4)	> 0.999
IgG index <sup>b</sup>	0.51 (0.29–3.69)	0.83 (0.22–2.20)	0.95
CSF leukocytes (cells/ $\mu$ L)	36 (2–221)	26 (0–150)	0.84
Symptom duration at CSF sampling (day)	16 (6–49)	35 (12–65)	0.08
Follow-up duration (mo)	16 (10–28)	21 (19–77)	0.17
Treatment delay > 4 wk	2 (28.6)	3 (42.9)	> 0.999
Teratoma	2 (28.6)	3 (42.9)	> 0.999

Values are presented as median (range) or number (%).

CSF, cerebrospinal fluid; CSF-OCB, CSF-restricted oligoclonal band; IV, intravenous; Ig, immunoglobulin.

<sup>a</sup>Number of patients. <sup>b</sup>Calculated using (CSF IgG/serum IgG)/(CSF albumin/serum albumin).

## Results

### Clinical characteristics

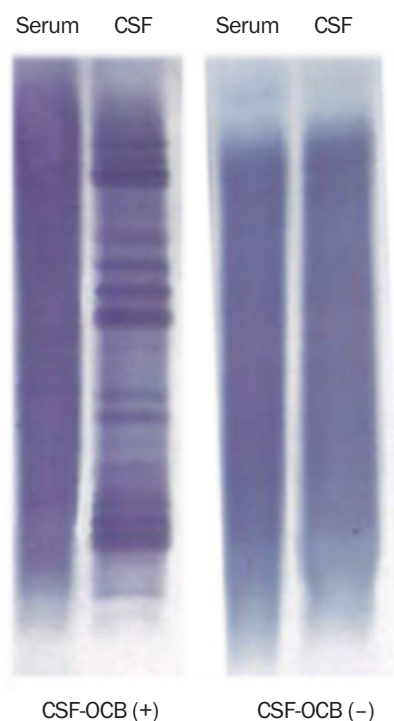
Fourteen confirmed NMDARE patients received initial CSF-OCB testing. Differences in age, sex, and symptom duration at CSF-OCB testing were not observed (Table 1). Nine patients (four CSF-OCB-negative patients and five CSF-OCB-positive patients) underwent CSF testing after intravenous immunoglobulins had been started.

Among the patients, seven were positive for CSF-OCBs (Figure 1) and seven were negative. Significant differences in the initial CSF findings between CSF-OCB-negative and CSF-OCB-positive groups including CSF leukocyte count and immunoglobulin G (IgG) index were not observed (Table 1). IgG index (baseline: mRS [ $p = 0.61$ ], CASE [ $p = 0.54$ ]; 12 months: mRS [ $p = 0.37$ ], CASE [ $p = 0.77$ ]) or the CSF leukocyte count (baseline: mRS [ $p = 0.95$ ], CASE [ $p = 0.92$ ]; 12 months: mRS [ $p = 0.80$ ], CASE [ $p = 0.89$ ]) correlated with initial and follow-up clinical severity.

The follow-up duration after testing between CSF-OCB-negative and CSF-OCB-positive groups did not differ significantly, and differences in the proportion of patients receiving delayed immunotherapy were not observed (Table 1). All patients received multiple courses of first-line, second-line, and other immunotherapies, and teratoma removal in case of teratoma discovery, as previously detailed [16].

### CSF-OCB positivity at disease onset is associated with marked differences in the initial severity and overall disease course

The mRS and CASE scores were significantly higher in CSF-OCB-positive patients than in CSF-OCB-negative patients at baseline, and 1, 3, 6, 9, and 12 months (Figure 2). Notably, an initial worsening of median CASE scores was observed in CSF-OCB-posi-

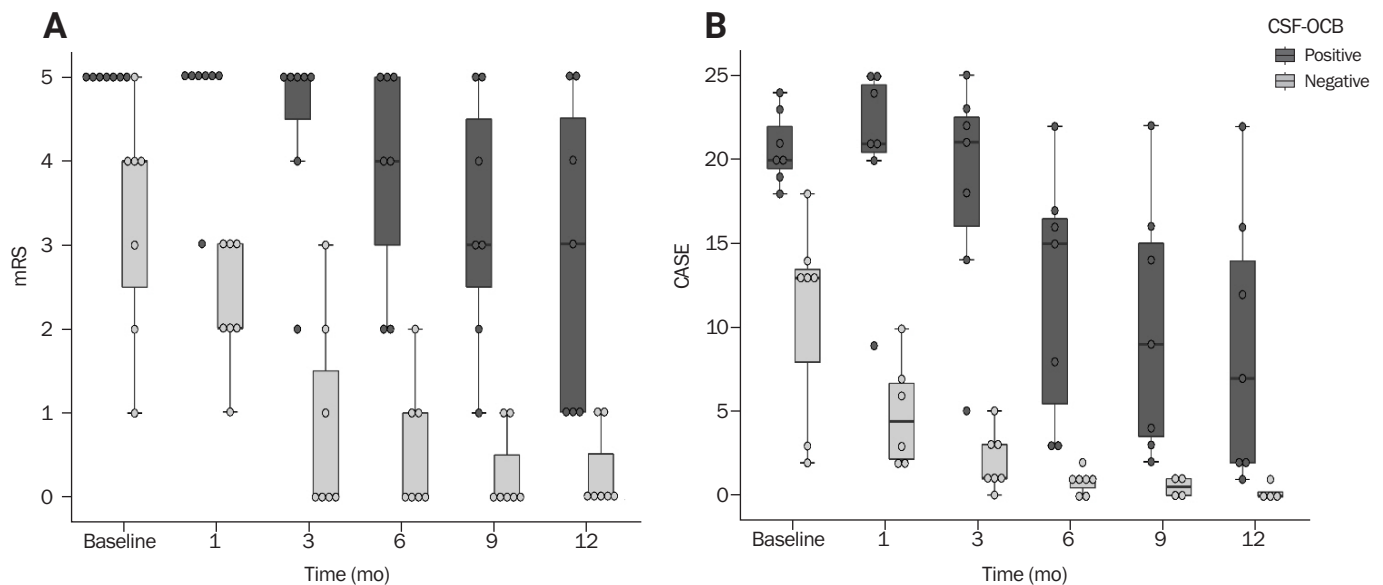
**Figure 1** Patterns of multiple CSF, CSF-OCBs in anti-N-methyl-D-aspartate receptor antibody encephalitis patients

Gel electrophoresis, isoelectric focusing with immunofixation results of paired sera and CSF samples.

CSF, cerebrospinal fluid; CSF-OCB, CSF-restricted oligoclonal band.

tive patients at 1 month after presentation, contrary to the rapid reduction in CASE scores in CSF-OCB-negative patients. In CSF-OCB-negative patients, the disease course was favorable and no patient had remaining sequela impairing daily life.

**Figure 2** One-year clinical trajectories in CSF-OCB-positive and CSF-OCB-negative patients



**(A)** Modified Rankin Scale (mRS). **(B)** Clinical assessment scale in autoimmune encephalitis (CASE). CSF-OCB, cerebrospinal fluid-restricted oligoclonal band.

**Table 2** Comparison of outcome variables between CSF-OCB-negative and CSF-OCB-positive groups

Variable	CSF-OCB-negative (n = 7)	CSF-OCB-positive (n = 7)	p-value
Total hospital stay (day)	19 (12–34)	173 (44–421)	< 0.001
Total ICU stay (day)	0 (0–2)	29 (0–54)	0.006
NEOS score	2 (0–3)	3 (2–4)	0.008
Lack of treatment response in first 4 wk	1 (14.3)	6 (85.7)	0.029
ICU admission	1 (14.3)	6 (85.7)	0.029
MRI abnormality	3 (42.9)	4 (57.1)	> 0.999
CSF leukocytes > 20/μL	3 (42.9)	4 (57.1)	> 0.999
<b>Modified Rankin Scale</b>			0.004
At baseline	4 (1–5)	5 (5–5)	
At 12 mo	0 (0–1)	3 (1–5)	0.005
<b>CASE</b>			
At baseline	13 (2–18)	20 (18–24)	0.002
At 12 mo	0 (0–1)	7 (1–22)	0.013
Seizure severity <sup>a</sup>	1 (0–2)	3 (2–3)	0.002
Maximum number of AEDs	3 (0–5)	6 (3–7)	0.028

Values are presented as median (range) or number (%).

CSF, cerebrospinal fluid; CSF-OCB, CSF-restricted oligoclonal band; ICU, intensive care unit; NEOS, anti-NMDA Receptor Encephalitis One-Year Functional Status; MRI, magnetic resonance imaging; CASE, clinical assessment scale in autoimmune encephalitis; AED, antiepileptic drug.

<sup>a</sup>Seizure severity: 0, no seizure; 1, controlled seizures; 2, uncontrolled seizures; 3, status epilepticus.

### CSF-OCB positivity predicts prolonged hospital stay and ICU admission

CSF-OCB positivity was associated with a longer duration of hospitalization ( $p < 0.001$ ) and ICU stay ( $p = 0.006$ , Table 2). Only one CSF-OCB-negative patient was admitted to the ICU

and five of seven CSF-OCB-positive patients stayed in the ICU longer than 2 weeks.

### CSF-OCB positivity indicates an increased risk of seizures

CSF-OCB-positive patients had more severe seizures and required administration of multiple AEDs (Table 2). No CSF-OCB-negative patient experienced status epilepticus; however, five CSF-OCB-positive patients experienced convulsive or non-convulsive status epilepticus with four requiring a trial of six or more concomitant administrations of AEDs. After 1 year of follow-up, four of seven CSF-OCB-positive patients remained dependent on multiple AEDs and only one CSF-OCB-negative patient was on a single AED.

### Presence of CSF-OCBs is predictive of important NEOS score components

CSF-OCB-positive patients were more likely to be admitted to the ICU ( $p = 0.029$ ) and have a lack of response to treatment in the first 4 weeks ( $p = 0.029$ ) than CSF-OCB-negative patients. Significant relationship was not observed between the presence of CSF-OCBs and MRI abnormality or CSF leukocyte count. Both NEOS score and CSF-OCB positivity predicted outcome at 12 months equally well (sensitivity, 100%; specificity, 64%; area under the receiver operating characteristic curve, 0.82).

## Discussion

In our NMDARE cohort, half of the patients were CSF-OCB-positive, somewhat comparable with previously reported prevalence ranging from 50% to 67% [17,18]. When the clinical correlation of CSF-OCB positivity was examined, the results showed a close association with early treatment refractoriness and ICU admission, greater clinical severity, and an initially deteriorating clinical course leading to prolonged hospital stays, uncontrolled seizures, and poorer outcome.

Other candidate prognostic markers have also been proposed. Anti-NMDAR antibody titers in the CSF were shown partially associated with clinical outcome [11] as well as other measurable factors such as cell-free CSF mitochondrial DNA [19], NLRP3 inflammasome levels [20], Th17 cells [21], and cytokines [22]; however, routinely tested CSF parameters were shown to not correlate with disease trajectory [9,10], as was the case in our cohort. CSF-OCB testing is advantageous because the test can be performed while a diagnosis of NMDARE is only suspected, and is widely available with an established method useful in many neurologic conditions.

Among the items of the NEOS score, treatment refractoriness in the first 4 weeks and ICU admission were the two strongest predictors of outcome [5]. Both factors closely paralleled CSF-OCB

positivity, and CSF-OCB positivity alone performed equally well as the NEOS score in predicting 1-year outcomes in our cohort.

The pathomechanistic implications of our results may be notable for two reasons. First, although in previous literature the focus was on a single antibody targeting the GluN1 subunit of the NMDAR as being pathogenic [23-25] and responsible for most symptoms [26-29] in NMDARE, the concomitant presence of oligoclonal antibodies appear to have clinical relevance. In MS, CSF-OCBs are thought to be produced by clonally expanded B cells within the intrathecal space [30] as a result of somatic hypermutation of B cells upon continued antigen presentation [31]. Therefore, CSF-OCBs in NMDARE could be a result of continued and prolonged exposure to antigens in the CNS triggering persistent immune response. This also may be the reason early removal of teratoma improves prognosis in NMDARE [32] and indicates multiple related antigenic targets that intensify disease pathology may exist in a portion of NMDARE patients. Another possibility is that CSF-OCBs reflect direct damage to the CNS and release various types of neural and glial antigens due to severe disease activity, and are not the cause.

Second, intrathecal humoral immune response appears closely associated with clinical severity in NMDARE. Among CSF-OCB-negative patients, the majority had a normal polyclonal pattern in both serum and CSF (five of seven; two had single bands in the CSF), and among CSF-OCB-positive patients, six of seven showed a normal polyclonal response in the serum. Thus, a distinct immune profile within the CNS was correlated with severe symptomatology, indicating intrathecal humoral immune response is primarily responsible for determining the clinical trajectory of NMDARE.

Lastly, a few issues should be considered when interpreting these results. Initial symptom severity in our cohort delineated patients with severe disease course from patients with milder disease course. Because clinical evaluations were made at similar time points as the lumbar puncture, any additional prognostic value beyond the initial clinical evaluation may be disputable. However, the CSF-OCBs have a practical advantage because they are a single diagnostic and prognostic biomarker, requiring no additional expert interpretation.

Further limitations of this study include the small sample size and the tertiary care setting with limited generalizability. However, the drastically contrasting clinical course of CSF-OCB-negative and CSF-OCB-positive patients that was clearly demonstrated in our small cohort, warrants further studies in which the relationship between CSF-OCB and clinical severity is investi-

gated.

In conclusion, the present study results indicate initial CSF-OCB testing in NMDARE may aid in identifying patients with unfavorable disease course and clearly stratifying patients into a severe and a benign group. Larger prospectively designed studies will help determine the clinical utility of initial OCB testing in NMDARE.

## Conflicts of Interest

Jangsup Moon, Kon Chu, Sang Kun Lee have been editorial board of *Encephalitis* since October 2020. They were not involved in the review process of this original article. No other potential conflict of interest relevant to this article was reported.

## Author Contributions

Conceptualization: SB Hong, YW Shin, K Chu, SK Lee; Data curation, Formal analysis, Project administration, Investigation: SB Hong; Methodology: SB Hong, YW Shin; Resources: K Chu, SK Lee; Supervision: YW Shin, J Moon, WJ Lee, K Chu, SK Lee; Writing–original draft: SB Hong; Writing–review and editing: SB Hong, YW Shin, J Moon.

## Acknowledgments

This work was supported by the National Research Foundation of Korea(NRF) grant funded by the Korea government (MSIT) (No. 2020R1C1C1014982).

## References

- Dalmau J, Lancaster E, Martinez-Hernandez E, Rosenfeld MR, Balice-Gordon R. Clinical experience and laboratory investigations in patients with anti-NMDAR encephalitis. *Lancet Neurol* 2011;10:63–74.
- de Montmollin E, Demeret S, Brulé N, et al. Anti-N-methyl-d-aspartate receptor encephalitis in adult patients requiring intensive care. *Am J Respir Crit Care Med* 2017;195:491–499.
- Lim JA, Lee ST, Jung KH, et al. Anti-N-methyl-d-aspartate receptor encephalitis in Korea: clinical features, treatment, and outcome. *J Clin Neurol* 2014;10:157–161.
- Wandinger KP, Saschenbrecker S, Stoecker W, Dalmau J. Anti-NMDA-receptor encephalitis: a severe, multistage, treatable disorder presenting with psychosis. *J Neuroimmunol* 2011;231:86–91.
- Balu R, McCracken L, Lancaster E, Graus F, Dalmau J, Titulaer MJ. A score that predicts 1-year functional status in patients with anti-NMDA receptor encephalitis. *Neurology* 2019;92:e244–e252.
- Irani SR, Bera K, Waters P, et al. N-methyl-D-aspartate antibody encephalitis: temporal progression of clinical and paraclinical observations in a predominantly non-paraneoplastic disorder of both sexes. *Brain* 2010;133:1655–1667.
- Titulaer MJ, McCracken L, Gabilondo I, et al. Treatment and prognostic factors for long-term outcome in patients with anti-NMDA receptor encephalitis: an observational cohort study. *Lancet Neurol* 2013;12:157–165.
- Dalmau J, Armangué T, Planagumà J, et al. An update on anti-NMDA receptor encephalitis for neurologists and psychiatrists: mechanisms and models. *Lancet Neurol* 2019;18:1045–1057.
- Schubert J, Brämer D, Huttner HB, et al. Management and prognostic markers in patients with autoimmune encephalitis requiring ICU treatment. *Neurol Neuroimmunol Neuroinflamm* 2018;6:e514.
- Wang R, Guan HZ, Ren HT, Wang W, Hong Z, Zhou D. CSF findings in patients with anti-N-methyl-D-aspartate receptor-encephalitis. *Seizure* 2015;29:137–142.
- Gresa-Arribas N, Titulaer MJ, Torrents A, et al. Antibody titres at diagnosis and during follow-up of anti-NMDA receptor encephalitis: a retrospective study. *Lancet Neurol* 2014;13:167–177.
- Arrambide G, Tintore M, Espejo C, et al. The value of oligoclonal bands in the multiple sclerosis diagnostic criteria. *Brain* 2018; 141:1075–1084.
- Graus F, Titulaer MJ, Balu R, et al. A clinical approach to diagnosis of autoimmune encephalitis. *Lancet Neurol* 2016;15:391–404.
- Shin YW, Lee ST, Kim TJ, Jun JS, Chu K. Bortezomib treatment for severe refractory anti-NMDA receptor encephalitis. *Ann Clin Transl Neurol* 2018;5:598–605.
- Lim JA, Lee ST, Moon J, et al. Development of the clinical assessment scale in autoimmune encephalitis. *Ann Neurol* 2019;85:352–358.
- Shin YW, Lee ST, Park KI, et al. Treatment strategies for autoimmune encephalitis. *Ther Adv Neurol Disord* 2017;11:1756285617722347.
- Blinder T, Lewerenz J. Cerebrospinal fluid findings in patients with autoimmune encephalitis—a systematic analysis. *Front Neurol* 2019;10:804.
- Dalmau J, Gleichman AJ, Hughes EG, et al. Anti-NMDA-receptor encephalitis: case series and analysis of the effects of antibodies. *Lancet Neurol* 2008;7:1091–1098.
- Peng Y, Zheng D, Zhang X, et al. Cell-free mitochondrial DNA in the CSF: a potential prognostic biomarker of anti-NMDAR encephalitis. *Front Immunol* 2019;10:103.
- Peng Y, Liu B, Pei S, et al. Higher CSF levels of NLRP3 inflammasome is associated with poor prognosis of anti-N-methyl-D-Aspartate receptor encephalitis. *Front Immunol* 2019;10:905.
- Zeng C, Chen L, Chen B, et al. Th17 cells were recruited and accumulated in the cerebrospinal fluid and correlated with the poor prognosis of anti-NMDAR encephalitis. *Acta Biochim Biophys Sin (Shanghai)*



- 2018;50:1266–1273.
22. Liba Z, Kayserova J, Elisak M, et al. Anti-N-methyl-D-aspartate receptor encephalitis: the clinical course in light of the chemokine and cytokine levels in cerebrospinal fluid. *J Neuroinflammation* 2016;13:55.
  23. Castillo-Gómez E, Oliveira B, Tapken D, et al. All naturally occurring autoantibodies against the NMDA receptor subunit NR1 have pathogenic potential irrespective of epitope and immunoglobulin class. *Mol Psychiatry* 2017;22:1776–1784.
  24. Hughes EG, Peng X, Gleichman AJ, et al. Cellular and synaptic mechanisms of anti-NMDA receptor encephalitis. *J Neurosci* 2010;30:5866–5875.
  25. Moscato EH, Peng X, Jain A, Parsons TD, Dalmau J, Balice-Gordon RJ. Acute mechanisms underlying antibody effects in anti-N-methyl-D-aspartate receptor encephalitis. *Ann Neurol* 2014;76:108–119.
  26. Jones BE, Tovar KR, Goehring A, et al. Autoimmune receptor encephalitis in mice induced by active immunization with conformationally stabilized holoreceptors. *Sci Transl Med* 2019;11:eaaw0044.
  27. Kreye J, Wenke NK, Chayka M, et al. Human cerebrospinal fluid monoclonal N-methyl-D-aspartate receptor autoantibodies are sufficient for encephalitis pathogenesis. *Brain* 2016;139:2641–2652.
  28. Ly LT, Kreye J, Jurek B, et al. Affinities of human NMDA receptor autoantibodies: implications for disease mechanisms and clinical diagnostics. *J Neurol* 2018;265:2625–2632.
  29. Wenke NK, Kreye J, Andrzejak E, et al. N-methyl-D-aspartate receptor dysfunction by unmutated human antibodies against the NR1 subunit. *Ann Neurol* 2019;85:771–776.
  30. Obermeier B, Mentele R, Malotka J, et al. Matching of oligoclonal immunoglobulin transcriptomes and proteomes of cerebrospinal fluid in multiple sclerosis. *Nat Med* 2008;14:688–693.
  31. Qin Y, Duquette P, Zhang Y, Talbot P, Poole R, Antel J. Clonal expansion and somatic hypermutation of V(H) genes of B cells from cerebrospinal fluid in multiple sclerosis. *J Clin Invest* 1998;102:1045–1050.
  32. Seki M, Suzuki S, Iizuka T, et al. Neurological response to early removal of ovarian teratoma in anti-NMDAR encephalitis. *J Neurol Neurosurg Psychiatry* 2008;79:324–326.

## Respiratory virus-related meningoencephalitis in adults

Seon-Jae Ahn<sup>1,2,\*</sup>, Jangsup Moon<sup>2,3,\*</sup>, Jun-Sang Sunwoo<sup>1,4</sup>, Jin-Sun Jun<sup>5</sup>, Soon-Tae Lee<sup>2</sup>, Kyung-Il Park<sup>2,6</sup>, Keun-Hwa Jung<sup>2</sup>, Ki-Young Jung<sup>2</sup>, Manho Kim<sup>2,7,8</sup>, Sang Kun Lee<sup>2,8</sup>, Kon Chu<sup>2</sup>

<sup>1</sup>Center for Hospital Medicine, Seoul National University Hospital, Seoul, Korea

<sup>2</sup>Department of Neurology, Seoul National University Hospital, Seoul, Korea

<sup>3</sup>Rare Disease Center, Seoul National University Hospital, Seoul, Korea

<sup>4</sup>Department of Neurosurgery, Seoul National University Hospital, Seoul, Korea

<sup>5</sup>Department of Neurology, Kangnam Sacred Heart Hospital, Hallym University College of Medicine, Seoul, Korea

<sup>6</sup>Department of Neurology, Seoul National University Hospital Healthcare System Gangnam Center, Seoul, Korea

<sup>7</sup>Protein Metabolism Medical Research Center, Seoul National University College of Medicine, Seoul, Korea

<sup>8</sup>Neuroscience Research Institute, Seoul National University College of Medicine, Seoul, Korea

### Purpose

Respiratory viruses (RVs) are pathogens that can cause central nervous system (CNS) infection, but previous research has been limited to a pediatric population. In recent years, several cases of adult RV meningoencephalitis have begun to be reported. We decided to research the CNS infection of RV in the entire neuroinfection registry.

### Methods

We retrospectively reviewed the neurologic infection registry of Seoul National University (Seoul, Korea). Among a total of 661 patients in the registry, 10 adult patients were diagnosed with RV-related meningoencephalitis on RV multiplex polymerase chain reaction (PCR) screening test. We analyzed the clinical presentation, laboratory findings, and clinical course of the 10 patients.

### Results

Three patients were definite RV meningoencephalitis who had positive PCR results from cerebrospinal fluid. The other seven patients were diagnosed with probable RV meningoencephalitis if they had positive PCR results in the sputum and negative results in other extensive workup.

### Conclusion

RV-related meningoencephalitis should be considered a possible etiology in adult meningoencephalitis patients. To diagnose these viruses, screening test of RV PCR is recommended even in patients without upper respiratory infection symptoms.

**Keywords:** Central nervous system viral infections, Meningitis, Encephalitis, Polymerase chain reaction

## Introduction

The respiratory virus (RV) group consists of viruses such as adenovirus; respiratory syncytial virus (RSV) A and B; rhinovirus A and B; coronavirus, influenza A and B; parainfluenza 1, 2, 3; and

metapneumovirus. RVs mainly cause upper or lower respiratory tract infections, but they can also cause central nervous system (CNS) infection, mostly in children [1]. Adult cases of RV-related meningoencephalitis have been reported in a limited number of patients, predominantly those with influenza virus [2]. How-

Received: November 8, 2020 Revised: November 14, 2020 Accepted: November 23, 2020

Correspondence: Kon Chu

Department of Neurology, Seoul National University Hospital, 101 Daehak-ro, Jongno-gu, Seoul 03080, Korea

E-mail: stemcell.snu@gmail.com

ORCID: <https://orcid.org/0000-0001-5863-0302>

\*These authors contributed equally to this study as co-first authors.

Copyright © 2021 by The Korean Encephalitis and Neuroinflammation Society

This is an open access article distributed under the terms of the Creative Commons Attribution Non-Commercial License (<http://creativecommons.org/licenses/by-nc/4.0/>) which permits unrestricted non-commercial use, distribution, and reproduction in any medium, provided the original work is properly cited.

ever, up to 66% of adult encephalitis cases fail to have a causative pathogen identified despite extensive diagnostic laboratory tests [3]. Therefore, further research is needed to identify unusual but detectable pathogens such as RV. We retrospectively reviewed the neurological infection registry, and analyzed the pathogenic etiology of the CNS infections, including the RVs.

## Methods

From March 2012 to December 2015, patients visiting Seoul National University Hospital (Seoul, Korea) with a clinical suspicion of CNS infection were enrolled in the neurological infection registry of Seoul National University Hospital (Seoul, Korea). The inclusion criteria were as follows; (1) clinical suspicion of CNS infection, (2)  $\geq 18$  years of age, and (3) cerebrospinal fluid (CSF) pleocytosis. The exclusion criteria were as follows; (1) CNS infection related to a recent surgical intervention, or (2) the presence of an additional etiology, such as autoimmune encephalitis or metabolic encephalopathy.

All patients in this registry underwent RV multiplex polymerase chain reaction (PCR) (Anyplex II RV 16 Detection; Seegene Inc., Seoul, Korea) analysis of CSF and sputum. This test provides qualitative analysis for 16 species of RV (adenovirus, influenza A and B, parainfluenza virus 1/2/3/4, rhinovirus A/B/C, RSV A and B, bocavirus 1/2/3/4, metapneumovirus, coronavirus 229E, coronavirus NL63, coronavirus OC43, and enterovirus). Other extensive diagnostic tests were performed, which included CSF culture, CSF PCR, and serum antibody tests for bacteria and viruses. Work-ups for rare pathogens such as tuberculosis, fungus, and parasites were also performed. A clinical diagnosis of meningitis or encephalitis was made based on the initial manifestation of symptoms. Meningitis was characterized by fever and headache without any neurological symptoms. Encephalitis was characterized by headache, altered level of consciousness, and symptoms and signs of cerebral dysfunction such as cognitive impairment, behavioral changes, focal neurologic abnormalities, and seizures [4]. Individual patients were treated according to clinical decisions made by an expert physician from the neurological infection department. Because of its retrospective nature, this study was exempted from the approval of the Institutional Review Board and the written informed consent of the subject.

## Results

A total of 661 patients were diagnosed with CNS infection and enrolled in the registry. Among these 661 CNS infection pa-

tients, 351 had meningitis, 275 encephalitis, and 35 brain abscess. Etiological pathogens were confirmed in 421 patients (63.7%). Viral infection (253, 60.1%) was the major etiology in pathogen-confirmed CNS infection, followed by bacterial infection (105, 24.9%), mycobacterial infection (25, 5.9%) and fungal infection (21, 5.0%). In pathogen-confirmed viral infection, EBV was the leading etiology (73, 28.9%) followed by herpes simplex virus (HSV; 62, 24.5%), varicella-zoster virus (VZV; 53, 20.9%), and enterovirus (51, 20.2%).

A total of 10 patients were diagnosed with RV-related meningoencephalitis. RV PCR of CSF or sputum yielded positive results, with no other findings on extensive workup. The median age of the patients was 38 years (range, 21–72 years). Four patients were clinically diagnosed with encephalitis and the others were diagnosed with meningitis. Six patients (60.0%) had prior upper respiratory infection (URI) symptoms before manifestation of CNS infection. Leptomeningeal enhancement was the most frequent finding (70.0%) observed on brain magnetic resonance imaging (MRI). Antiviral therapy was administered in 3 of 4 encephalitis patients and 2 of 7 meningitis patients. All of the patients recovered fully without any neurological sequelae, except for one patient (patient 3) who deteriorated despite antiviral treatment (Table 1).

We classified these patients into two different groups according to PCR results. The first was the “definite” group, in which RV presence was confirmed by CSF PCR, and the second was the “probable” group, in which RV presence could be confirmed only by sputum PCR.

### Definite respiratory virus meningoencephalitis

Three patients were classified into the “definite” group. Two patients had positive PCR results for influenza A in CSF. The other patient had positive results for human parainfluenza 3 virus in CSF.

Patient 1 was a 40-year-old female. She visited the emergency room for altered mentality and fever lasting 5 days. Before the onset of neurologic symptoms, she complained of cough, rhinorrhea, and mild fever. Initial CSF revealed pleocytosis with a white blood cell (WBC) count of  $129/\text{mm}^3$  (polymorphonucleocytes, 82%; lymphocytes, 4%; other cells, 14%), and elevated protein (153 mg/dL). Initial brain MRI showed leptomeningeal enhancement, but electroencephalography (EEG) did not demonstrate abnormal findings. On extensive diagnostic workup, CSF PCR was positive for influenza A virus. She was treated with oseltamivir and recovered fully after 2 weeks of antiviral therapy; she was discharged at a modified Rankin Scale (mRS)

**Table 1** Characteristics of the respiratory virus-related meningoencephalitis patients

Case No.	Age (yr) /sex	Initial symptom	Clinical manifestation	PCR		Positive virus	CSF WBC count, /mm <sup>3</sup> (% of P/L/O)	MRI finding	EEG finding	Antiviral therapy	Onset to treat (day)	Outcome (mRS)
				CSF	Sputum							
1	40/F	URI, fever, altered mentality	Encephalitis	+	ND	Influenza A	129 (82/4/14)	LE	Normal	Oseltamivir	9	0
2	21/M	Fever, headache, seizure	Encephalitis	+	ND	Human parainfluenza 3	139 (34/48/18)	LE	Normal	Ribavirin	35	0
3	67/M	URI, irritability, confusion	Encephalitis	+	+	Influenza A (CSF) Metapneumovirus (sputum)	25 (20/80/0)	SAH, LE	Slowing	Oseltamivir	40	5
4	69/M	Confusion, fever, gait disturbance	Encephalitis	ND	+	Human parainfluenza 2	13 (0/1/12)	Normal	Slowing	NA	NA	0
5	25/F	URI, fever, headache	Meningitis	ND	+	Human rhinovirus A/B	194 (5/90/5)	NA	Normal	NA	NA	0
6	45/F	URI, fever, headache	Meningitis	ND	+	Influenza A	50 (0/42/8)	LE	Normal	Oseltamivir	10	0
7	35/M	URI, headache	Meningitis	ND	+	Human rhinovirus A/B	385 (0/84/16)	Normal	Normal	NA	NA	0
8	33/M	URI, fever, headache	Meningitis	ND	+	Human RSV A	210 (2/95/3)	LE	NA	NA	NA	0
9	72/M	Headache	Meningitis	ND	+	Human coronavirus 229E/NL63	940 (66/20/14)	LE	NA	NA	NA	0
10	28/M	Fever, headache	Meningitis	ND	+	Influenza B Human RSV A	216 (4/72/24)	LE	Normal	Oseltamivir	7	0

PCR, polymerase chain reaction; CSF, cerebrospinal fluid; WBC, white blood cell; P, polymorphonuclear leukocytes; L, lymphocytes; O, other cells; MRI, magnetic resonance imaging; EEG, electroencephalography; mRS, modified Rankin Scale; F, female; M, male; URI, upper respiratory infection; LE, leptomeningeal enhancement; SAH, subarachnoid hemorrhage; RSV, respiratory syncytial virus; ND, not detected; NA, not available.

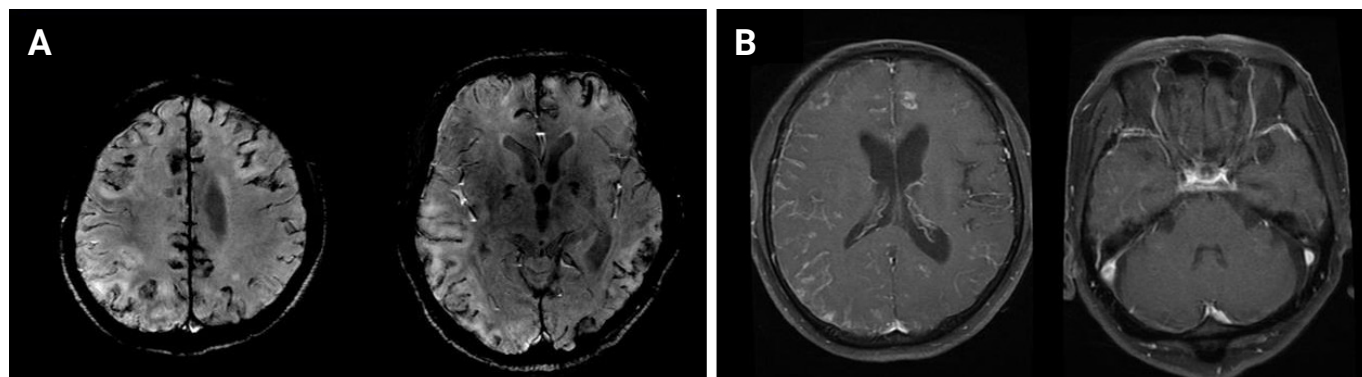
score of 0.

Patient 2 was a 21-year-old male who presented with first-onset seizure. He had a generalized tonic-clonic seizure after complaining of headache for 5 days. Initial CSF showed pleocytosis with red blood cells (RBC) of 12/mm<sup>3</sup>, a WBC of 139/mm<sup>3</sup> (polymorphonucleocytes, 34%; lymphocytes, 48%; other cells, 18%), and elevated protein (52 mg/dL). RV PCR of CSF was positive for human parainfluenza virus 3; otherwise, there were no abnormal findings on extensive diagnostic workup. Brain MRI showed leptomeningeal enhancement and EEG demonstrated no focal epileptiform discharge but did reveal generalized intermittent rhythmic delta activity. He was treated with ribavirin for 1 week, after which he was clinically recovered and did not complain of any headache or seizure. Follow-up EEG was also normal after ribavirin treatment.

Patient 3 was a 67-year-old male who had been hospitalized previously for headache, right-side weakness, and transcortical motor aphasia. Prior to headache, he suffered from cough and rhinorrhea for 1 month. Brain computed tomography at a previous hospital showed cortical subarachnoid hemorrhage (SAH). He was treated with corticosteroids in order to reduce intracranial pressure. Initial CSF results revealed pleocytosis with RBC of 270/mm<sup>3</sup>, WBC of 25/mm<sup>3</sup> (lymphocytes, 80%; polymorphonucleocytes, 20%), and elevated protein (214.7 mg/dL). He recovered partially and was discharged after 1 week of steroid treatment. However, before long, he started to show confused mentality again and was transferred to our hospital for a second opinion. Follow-up CSF analysis in our hospital revealed persistent pleocytosis with an RBC of 18/mm<sup>3</sup> and WBC of 16/mm<sup>3</sup> (lymphocytes, 13; other cells, 3), and elevated protein (137 mg/dL). On RV PCR, the CSF specimen was positive for influenza A and the sputum specimen was positive for human metapneumovirus. On brain MRI, cortical SAH (Figure 1A) was aggravated and leptomeningeal enhancement (Figure 1B) was observed. Initially, acyclovir was administered for 1 week but was changed to oseltamivir after CSF PCR results were obtained. Although we treated him with oseltamivir for 2 weeks and follow-up CSF PCR results were negative, his mental status worsened. Finally, we administered intravenous peramivir, but the patient entered a persistent vegetative state (mRS score 5) without clinical response.

**Probable respiratory virus meningoencephalitis**

We classified the other seven patients into the clinically “probable” group. Patients in this group were clinically diagnosed with meningoencephalitis and no pathogens were found on extensive workup other than positive RV PCR of sputum. There were

**Figure 1** Brain MRI of a respiratory virus-related encephalitis patient with a poor outcome (patient 3)**(A)** Diffuse cortical subarachnoid hemorrhage on susceptibility-weighted angiography MRI. **(B)** Leptomeningeal enhancement on T1-weighted contrast-enhanced MRI.

MRI, magnetic resonance imaging.

two human rhinovirus A/B infections, one of influenza A, one of human parainfluenza virus 2, one human coronavirus 229E/NL63, and one case with both influenza B and human RSV A. Four of these patients had URI symptoms prior to headache. Two patients whose PCR results were positive for influenza A were treated with oseltamivir, and the other patients underwent conservative management. Four patients exhibited leptomeningeal enhancement on MRI. Specific clinical information is presented in [Table 1](#).

## Discussion

Here, we demonstrated that, although rare, RVs can be a causative pathogen of meningoencephalitis in adults. According to our data from an adult population, 1.5% of total CNS infection patients were diagnosed with RV-related meningoencephalitis. This accounts for 4.0% of the total CNS viral infections.

Recently, neurologic manifestations of respiratory viral infection have come to the fore. RVs can invade the CNS through either a hematogenous route or a peripheral nerve route [5]. Many cases of RV-associated meningoencephalitis have been reported in adult patients with adenovirus [6], bocavirus [7], influenza A [8-10], influenza B [11,12], parainfluenza [13], and metapneumovirus [14-17]. Reports of meningoencephalitis caused by diverse types of RVs are more common in pediatric cases. RV-related encephalitis comprises approximately 20% of all encephalitis cases in children aged 1 month to 15 years [2]. However, even in adults, RVs remain an important pathogenic cause of meningoencephalitis around the world.

The diagnostic strategy for RV-related meningoencephalitis is similar to other infectious meningoencephalitis. PCR and real time-PCR assays of CSF for the detection of viruses are the most reliable diagnostic tools. A wide range of PCR tests should be carried out, including RV panel, HSV-1, HSV-2, VZV, CMV, and enterovirus, among others. Serologic tests, including serum and CSF specimens, are also helpful to specific etiological diagnosis. In the case of respiratory viral infection, we believe PCR testing of sputum will help establish a diagnosis [18].

Detailed history taking about prodromal symptoms, recent travel, geographic location, exposure history, and occupation provides important clinical clues regarding infectious pathogens. Nevertheless, clinical symptoms and neurologic examination findings are similar among CNS infections. In our study, it is remarkable that a considerable portion of RV-related meningoencephalitis patients (4 of 10) did not have URI symptoms. In 2009, a prospective longitudinal study showed that respiratory pathogens are frequently detected in samples not only from children with respiratory symptoms (56%) but also from those without respiratory symptoms (40%) [19]. Therefore, we believe that a respiratory PCR panel should be routinely conducted in patients with suspected CNS infections.

Most RV-related meningoencephalitis patients showed favorable outcomes. RV-related encephalitis is treatable with properly timed antiviral therapy. In particular, influenza A encephalitis can be treated with antiviral therapy [20,21]. Influenza A encephalitis can be fatal not only in children but also in adults [22-24]. Cortical SAH can develop from influenza A infection [25,26]. In our cases, patient 3 showed a poor clinical outcome despite

antiviral treatment. He already had a cortical SAH long before antiviral treatment began. The delay between onset and administration of the antiviral agent could be the reason why he was the only patient with clinical deterioration. This case showed the importance of fast and accurate diagnosis of RV-related meningoencephalitis [27]. Ribavirin, a broad-spectrum antiviral agent, is used to treat *Paramyxoviridae* pneumonia, such as human RSV, parainfluenza virus, and metapneumovirus [28]. Intravenous ribavirin was effective in Nipha-virus encephalitis [29], which is caused by another *Paramyxoviridae* disease. In our study, patient 2 was also successfully treated with ribavirin. Ribavirin is the treatment of choice when any patient is infected with RVs like those described above.

Our study has some limitations in the certainty of diagnosis. Because of the low detectability of viral nucleic acids in CSF, many cases of encephalitis were diagnosed based on the results of serological tests, antigen detection, viral culture, and nucleic acid detection from sputum, stool, urine, or blood [4]. Positive PCR results from sputum also can be indirect evidence of a diagnosis. Previous studies of RV-related meningoencephalitis and other studies of CNS infection etiology have used these indirect methods for specific etiological diagnosis [3]. Nevertheless, these indirect tools provide a lower level of confidence than PCR results from CSF and have the possibility of detecting asymptomatic coinfections limited to the upper respiratory system. This is an unavoidable limitation of our study. Therefore, we chose to divide the patients into two groups based on the certainty of diagnosis.

In conclusion, this is the first etiological study of adult RV-related meningoencephalitis in a large CNS infection registry. Clinicians should keep in mind that, although rare, RVs can cause acute meningoencephalitis in adult patients, even in those without URI symptoms.

## Conflicts of Interest

Jangsup Moon, Soon-Tae Lee, Kyung-Il Park, Keun-Hwa Jung, Sang Kun Lee, Kon Chu have been editorial board of *Encephalitis* since October 2020. They were not involved in the review process of this original article. No other potential conflict of interest relevant to this article was reported.

## Author Contributions

Conceptualization: ST Lee, K Chu; Data curation: SJ Ahn; Formal analysis: SJ Ahn, J Moon; Funding acquisition: M Kim;

Methodology: SJ Ahn, K Chu; Visualization: SJ Ahn, JS Jun; Supervision: J Sunwoo, ST Lee, KI Park, KH Jung, KY Jung, M Kim, SK Lee, K Chu; Validation: KI Park, KH Jung, KY Jung, M Kim, SK Lee; Writing—original draft: SJ Ahn, J Moon; Writing—review & editing: SJ Ahn, J Moon, J Sunwoo, JS Jun, K Chu.

## Acknowledgements

This work was supported by the Brain Research Program through the National Research Foundation of Korea (NRF) funded by the Ministry of Science, ICT & Future Planning (NRF-2016M33C7A1914002).

## References

1. Koskiniemi M, Korppi M, Mustonen K, et al. Epidemiology of encephalitis in children. A prospective multicentre study. *Eur J Pediatr* 1997; 156:541–545.
2. Koskiniemi M, Rantalaiho T, Piiparinen H, et al. Infections of the central nervous system of suspected viral origin: a collaborative study from Finland. *J Neurovirol* 2001;7:400–408.
3. Kupila L, Vuorinen T, Vainionpää R, Hukkanen V, Marttila RJ, Kotilainen P. Etiology of aseptic meningitis and encephalitis in an adult population. *Neurology* 2006;66:75–80.
4. Steiner I, Budka H, Chaudhuri A, et al. Viral encephalitis: a review of diagnostic methods and guidelines for management. *Eur J Neurol* 2005;12:331–343.
5. Bohmwald K, Gálvez NMS, Ríos M, Kalergis AM. Neurologic alterations due to respiratory virus infections. *Front Cell Neurosci* 2018; 12:386.
6. Fianchi L, Scardocci A, Cattani P, Tartaglione T, Pagano L. Adenovirus meningoencephalitis in a patient with large B-cell lymphoma. *Ann Hematol* 2003;82:313–315.
7. Mori D, Ranawaka U, Yamada K, et al. Human bocavirus in patients with encephalitis, Sri Lanka, 2009–2010. *Emerg Infect Dis* 2013; 19:1859–1862.
8. Santini M, Kutleša M, Zarković K, Draženović V, Barsic B. Influenza A 2009 H1N1 encephalitis in adults with viral RNA in cerebrospinal fluid. *Scand J Infect Dis* 2012;44:992–996.
9. Cunha BA, Fear GL, Chawla K. A rare case of influenza A in a hospitalized adult presenting with encephalitis and a seizure. *IDCases* 2018; 12:153–155.
10. Midha D, Kumar A, Vasudev P, Iqbal ZA, Mandal AK. Adult influenza A (H1N1) related encephalitis: a case report. *Indian J Crit Care Med* 2018;22:384–387.
11. McCullers JA, Facchini S, Chesney PJ, Webster RG. Influenza B virus encephalitis. *Clin Infect Dis* 1999;28:898–900.

12. Ak Ö, Biteker F, Cag Y, et al. Influenza B-associated encephalopathy in two adults. *J Infect Chemother* 2012;18:961–964.
13. Craver RD, Gohd RS, Sundin DR, Hierholzer JC. Isolation of parainfluenza virus type 3 from cerebrospinal fluid associated with aseptic meningitis. *Am J Clin Pathol* 1993;99:705–707.
14. Tan YL, Wee TC. Adult human metapneumovirus encephalitis: a case report highlighting challenges in clinical management and functional outcome. *Med J Malaysia* 2017;72:372–373.
15. Jeannet N, van den Hoogen BG, Schefold JC, Suter-Riniker F, Sommerstein R. Cerebrospinal fluid findings in an adult with human metapneumovirus-associated encephalitis. *Emerg Infect Dis* 2017; 23:370.
16. Fok A, Mateevici C, Lin B, Chandra RV, Chong VH. Encephalitis-associated human metapneumovirus pneumonia in adult, Australia. *Emerg Infect Dis* 2015;21:2074–2076.
17. Sánchez Fernández I, Rebollo Polo M, Muñoz-Almagro C, et al. Human metapneumovirus in the cerebrospinal fluid of a patient with acute encephalitis. *Arch Neurol* 2012;69:649–652.
18. Tyler KL. Acute viral encephalitis. *N Engl J Med* 2018;379:557–566.
19. van der Zalm MM, van Ewijk BE, Wilbrink B, Uiterwaal CS, Wolfs TF, van der Ent CK. Respiratory pathogens in children with and without respiratory symptoms. *J Pediatr* 2009;154:396–400.
20. Fox J, Barbour S, Junco SJ. Central nervous system laboratory-confirmed influenza meningo-encephalitis treated with peramivir. *Int J Antimicrob Agents* 2018;52:517–518.
21. Alsolami A, Shiley K. Successful treatment of influenza-associated acute necrotizing encephalitis in an adult using high-dose oseltamivir and methylprednisolone: case report and literature review. *Open Forum Infect Dis* 2017;4:ofx145.
22. Simon M, Hernu R, Cour M, Casalegno JS, Lina B, Argaud L. Fatal influenza A(H1N1)pdm09 encephalopathy in immunocompetent man. *Emerg Infect Dis* 2013;19:1005–1007.
23. Akins PT, Belko J, Uyeki TM, Axelrod Y, Lee KK, Silverthorn J. H1N1 encephalitis with malignant edema and review of neurologic complications from influenza. *Neurocrit Care* 2010;13:396–406.
24. Fugate JE, Lam EM, Rabinstein AA, Wijdicks EF. Acute hemorrhagic leukoencephalitis and hypoxic brain injury associated with H1N1 influenza. *Arch Neurol* 2010;67:756–758.
25. AbdelRazek MA, Leone MJ, Venna N. Hemorrhagic encephalitis associated with H3N2 influenza A viral pneumonia. *Neurology* 2018; 90:336–337.
26. Takeda H, Isono M, Kobayashi H. Possible acute hemorrhagic leukoencephalitis manifesting as intracerebral hemorrhage on computed tomography: case report. *Neurol Med Chir (Tokyo)* 2002;42:361–363.
27. Meijer WJ, Linn FH, Wensing AM, et al. Acute influenza virus-associated encephalitis and encephalopathy in adults: a challenging diagnosis. *JMM Case Rep* 2016;3:e005076.
28. Abed Y, Boivin G. Treatment of respiratory virus infections. *Antiviral Res* 2006;70:1–16.
29. Chong HT, Kamarulzaman A, Tan CT, et al. Treatment of acute Nipah encephalitis with ribavirin. *Ann Neurol* 2001;49:810–813.

## Refractory neuro-Sweet disease successfully treated with tocilizumab and mycophenolate mofetil

Sungeun Hwang<sup>1,2</sup>, Hyoshin Son<sup>1,2</sup>, Jangsup Moon<sup>1,2,3</sup>, Soon-Tae Lee<sup>1,2</sup>, Keun Hwa Jung<sup>1,2</sup>, Kyung-II Park<sup>1,2,4</sup>, Sang Kun Lee<sup>1,2</sup>, Kon Chu<sup>1,2</sup>

<sup>1</sup>Department of Neurology, Seoul National University Hospital, Seoul, Korea

<sup>2</sup>Laboratory for Neurotherapeutics, Center for Medical Innovations, Biomedical Research Institute, Seoul National University Hospital, Seoul, Korea

<sup>3</sup>Rare Disease Center, Seoul National University Hospital, Seoul, Korea

<sup>4</sup>Department of Neurology, Seoul National University Hospital Healthcare System Gangnam Center, Seoul, Korea

Sweet syndrome, or acute febrile neutrophilic dermatosis, is mainly a dermatologic condition presenting with erythematous plaques; however, neutrophils infiltrate multiple systems. Neuro-Sweet disease is a neurological manifestation of Sweet syndrome and a rare cause of recurrent aseptic meningoencephalitis, which needs to be distinguished from neuro-Behçet disease. Although neuro-Sweet disease generally responds well to corticosteroids, relapsing neuro-Sweet disease is not an exceptional case. Herein, we present a case of a 51-year-old male with recurrent encephalitis followed by erythematous plaques. The patient was confirmed as Sweet syndrome based on skin biopsy and showed partial response to corticosteroids. With intravenous immunoglobulin, rituximab, tocilizumab, and mycophenolate mofetil, his neurologic symptoms were fully recovered.

**Keywords:** Sweet syndrome, Tocilizumab, Mycophenolic acid

### Introduction

Sweet syndrome (acute febrile neutrophilic dermatosis) was first described by Dr. Robert Douglas Sweet in 1964 [1]. The syndrome is characterized by fever, neutrophilic leukocytosis, and tender erythematous plaques. Biopsy of erythematous plaques shows a dense dermal infiltration with mature neutrophils. Response to corticosteroid treatment is generally rapid and favorable. Neurological manifestation of Sweet syndrome, termed neuro-Sweet disease, is a rare cause of aseptic meningoencephalitis. Neuro-Sweet disease also responds to corticosteroids, however, refractory cases with multiple relapses have occurred. Herein, we report a case of a patient with refractory neuro-Sweet disease, who was successfully treated with intravenous immunoglobulin (IVIG), rituximab, tocilizumab, and mycophenolate mofetil.

### Case Report

A 51-year-old male with a history of recurrent episodes of unconsciousness (10, 7, 2 years, and 4 months before the current visit) presented with cognitive impairment. The patient was admitted to another hospital for altered mental state 10 and 7 years before the current visit. Although no definitive diagnosis was made, his consciousness was restored with supportive treatment. When visiting another hospital 2 years before his current visit (May 2016), the patient had erythematous plaques on the neck and legs accompanied by headache, myalgia, febrile sense, and unconsciousness. On admission to our hospital, a brain magnetic resonance imaging (MRI) scan showed T2 hyperintensities on bilateral basal ganglia, frontal, temporal, and insular subcortices (Figure 1A and B). Biopsy of the posterior neck skin lesion on admission revealed dermal neutrophilic infiltration

Received: November 16, 2020 Revised: December 1, 2020 Accepted: December 1, 2020

Correspondence: Kon Chu

Department of Neurology, Seoul National University Hospital, 101 Daehak-ro, Jongno-gu, Seoul 03080, Korea

E-mail: [stemcell.snu@gmail.com](mailto:stemcell.snu@gmail.com)

ORCID: <https://orcid.org/0000-0001-5863-0302>

Copyright © 2021 by The Korean Encephalitis and Neuroinflammation Society

This is an open access article distributed under the terms of the Creative Commons Attribution Non-Commercial License (<http://creativecommons.org/licenses/by-nc/4.0/>) which permits unrestricted non-commercial use, distribution, and reproduction in any medium, provided the original work is properly cited.



compatible with Sweet syndrome. The patient received symptomatic treatments and erythematous plaques were resolved without corticosteroid therapy. Brain MRI after 2 months showed resolution of bilateral basal ganglia and subcortical T2 hyperintense lesions (Figure 1C and D).

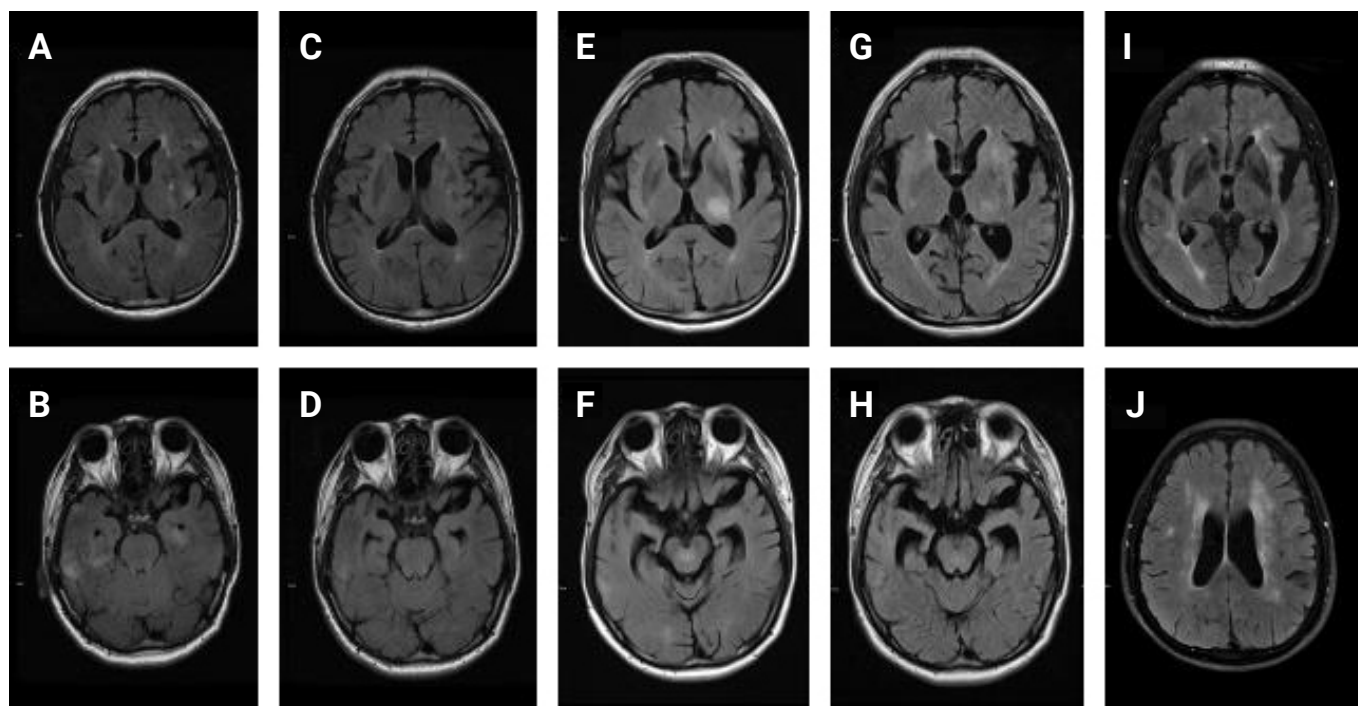
The patient presented 4 months earlier (January 2018) with sore throat, headache, myalgia, febrile sense, unconsciousness, and erythematous nodules on his face spreading to the whole body. T2 hyperintense lesions were observed in the left thalamus, midbrain, and pons on brain MRI scan (Figure 1E and F). After treatment with high-dose corticosteroids for 5 days, his symptoms improved and T2 hyperintensities on brain MRI scan disappeared (Figure 1G and H). However, he complained of persistent dysarthria and cognitive impairment for months.

The subject was admitted to our center for further treatment in May 2018. Neurologic examination revealed mild dysarthria without other cranial nerve dysfunction. Fever and erythematous plaques were absent on admission. Neutrophilia (leukocytes, 14,880/ $\mu$ L; neutrophils, 11,859/ $\mu$ L; 79.7% of neutrophils)

and elevated C-reactive protein (CRP) level (1.17 mg/dL) were observed despite oral prednisolone maintenance (10 mg/day) for the preceding 4 months. Cerebrospinal fluid examination was unremarkable. Viral, fungal, tuberculous, or bacterial pathogens were not detected. Human leukocyte antigen (HLA) typing confirmed HLA-B52/B54. Mini-mental state examination score was 25 of 30 with impaired memory registration, recall, and calculation. Frontal assessment battery showed decreased word fluency. Clinical assessment scale for autoimmune encephalitis (CASE) score was 3 and modified Rankin scale (mRS) score was 2 [2].

IVIg treatment (400 mg/kg/day for 5 days) was initiated followed by weekly rituximab (375 mg/m<sup>2</sup> for 4 weeks). After the 2nd administration of rituximab, dysarthria and language fluency were slightly improved (CASE score, 2; mRS score, 2). After the 4th dose of rituximab, brain MRI scan showed new T2 hyperintensities on bilateral frontal, temporal, and insular subcortices (Figure 1I and J). However, neurologic deterioration was not observed and four cycles of monthly rituximab therapy were

**Figure 1** Serial MRI scan images (fluid attenuated inversion recovery images)



MRI scan in May 2016 (A, B) shows T2 hyperintense lesions in bilateral basal ganglia and subcortical frontal, temporal, and insular lobes, which were reduced on follow-up MRI scan in July 2016 (C, D). (E, F) New T2 hyperintense lesions in left thalamus, midbrain, and pons were observed in February 2018. (G, H) Partial resolution of previous lesions was observed in March 2018. (I, J) In June 2018, MRI scan revealed bilateral subcortical T2 hyperintensities in bilateral frontal, temporal, insular, and parietal lobes. These lesions remained on follow-up MRIs in December 2018 and May 2019 (not shown).

MRI, magnetic resonance imaging.

maintained. Dysarthria or language dysfunction was not observed but mild memory dysfunction remained (CASE score, 1; mRS score, 1).

In November 2018, an erythematous rash developed without neurologic deterioration. Oral mycophenolate mofetil (500 mg/day) and high-dose corticosteroid were initiated resulting in resolution of erythematous plaques. Intravenous tocilizumab (6 mg/kg every month) was administered from December 2018 to June 2019. Erythematous plaques recurred in February and May 2019 (Figure 2A), which resolved with tocilizumab (and combined high-dose intravenous corticosteroid in February 2019). Skin biopsy from a plaque on the posterior neck in May 2019 (Figure 2B) revealed dermal neutrophilic infiltration suggestive of Sweet syndrome. After the 6th injection of tocilizumab, only mycophenolate mofetil was maintained without recurrence of rash and neurologic symptoms. Mycophenolate mofetil was discontinued in December 2019. Rash and neurologic symptoms

did not relapse until the last visit in March 2020 (CASE score, 0; mRS score, 0). Time course of immunotherapies and clinical events are depicted in Figure 3.

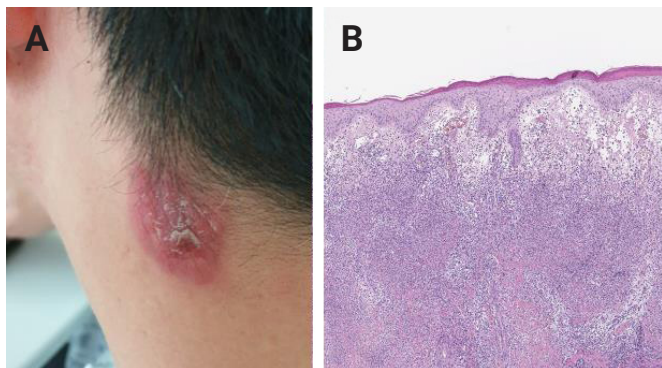
Written informed consent was obtained for publication of this case report and accompanying images.

### Discussion

Sweet syndrome (acute febrile neutrophilic dermatosis) is characterized by fever, leukocytosis, and tender erythematous skin lesions [1]. Erythema typically involves head, neck, and limbs. Leukocytosis (neutrophilia) and elevated CRP and erythrocyte sedimentation rate are common laboratory findings. Skin biopsy shows dermal neutrophilic infiltration in the absence of vasculitis. Although skin is most commonly involved, other organs such as eyes, liver, kidneys, and lungs can be infiltrated with neutrophils [3]. Response to corticosteroid is favorable, resulting in complete remission without scarring in most cases [4].

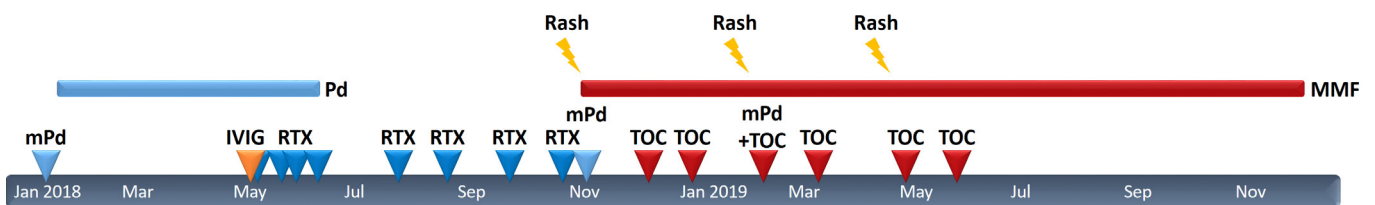
Neurologic manifestation of Sweet syndrome, termed neuro-Sweet disease, has been reported since the 1990s [5]. Common presentation of neuro-Sweet disease is aseptic meningoen- cephalitis with or without erythematous plaques [3]. Various symptoms such as altered consciousness, headache, cognitive impairment, aphasia, or peripheral neuropathy can be observed. Typically, erythematous plaques precede neurologic symptoms; however, cases of encephalitis followed by skin involvement or cases without erythematous plaques have been reported [6]. Computed tomography or MRI scans reveal multiple central nervous system lesions [3]. Basal ganglia and brainstem are frequently involved similar to neuro- Behçet disease. Because skin is commonly involved in neuro-Sweet disease and neuro- Behçet disease, differentiating these two conditions is important. In neuro- Behçet disease, skin biopsy shows vasculi-

**Figure 2** Posterior neck plaque in May 2019



(A) Erythematous plaque on left posterior neck. (B) Skin biopsy of erythematous plaque on left posterior neck (H&E stain, ×40). Mixed lymphohistiocytic and numerous neutrophilic infiltrations in dermis.

**Figure 3** Time course of immunotherapies and clinical events



Arrows and bars on the timelines indicate the timing/duration of each immunotherapy. Yellow lightning indicates timing of relapsed erythematous plaques.

mPd, intravenous high-dose methylprednisolone; Pd, oral prednisolone; IVIG, intravenous immunoglobulin; RTX, rituximab; TOC, tocilizumab; MMF, mycophenolate mofetil.

tis in contrast to dermal neutrophilic infiltration in neuro-Sweet disease. Neuro-Sweet disease usually responds to corticosteroids, and in some cases supportive treatment can lead to spontaneous remission. HLA-B54 (63% in neuro-Sweet disease vs. 14% in Japanese population) and HLA-Cw (89% in neuro-Sweet disease vs. 28% in Japanese population) are frequently detected in patients with neuro-Sweet disease [3]. Although recurrence is common, there is no established preventive therapy to date. Conversely, response to corticosteroids is poor and HLA-B51 is frequently detected in patients with neuro-Behçet disease [7].

Treatment options other than corticosteroids include colchicine and potassium iodide as first-line treatment options for dermal involvement of Sweet syndrome [8]. Nonsteroidal anti-inflammatory drugs, dapsone, clofazimine, cyclosporine, and thalidomide are second-line therapies. There are reports of effective treatment of Sweet syndrome with methotrexate, interferon- $\alpha$ , IVIG, anakinra, or anti-tumor necrosis factor (TNF)- $\alpha$  [8,9]. Rituximab (anti-CD20 monoclonal antibody) and tocilizumab (anti-interleukin-6 monoclonal antibody) have shown efficacy in case reports of refractory Sweet syndrome [10,11]. However, possible anti-TNF- $\alpha$ - or tocilizumab-induced Sweet syndrome has been reported, and the effectiveness of these drugs remains controversial [12].

In the present case, the patient had a history of recurrent neuro-Sweet syndrome. Because skin was involved years after the initial neurologic manifestation, he experienced a diagnostic odyssey. He was undiagnosed until the erythematous plaques appeared 2 years before the current visit, which prompted skin biopsy confirming the diagnosis of neuro-Sweet disease. Despite spontaneous remission after supportive treatment 10, 7, and 2 years earlier, high-dose corticosteroid treatment induced partial remission 4 months before the current visit. Dysarthria and cognitive impairment remained even with long-term maintenance of oral corticosteroid. Additional immunotherapy with IVIG, rituximab, mycophenolate mofetil, and tocilizumab induced complete remission of neuro-Sweet disease without neurologic sequela.

The present case demonstrates efficacy of multiple immunotherapies in neuro-Sweet disease. Although numerous reports of dermal manifestation of Sweet syndrome treated with immunomodulatory drugs exist, reports on immunotherapy treatment in neuro-Sweet disease are limited. Reportedly, cyclosporine, dapsone, and infliximab (TNF- $\alpha$  inhibitor) have been used in cases of corticosteroid-resistant or corticosteroid-dependent neuro-Sweet disease [13,14]. To the best of our knowledge, this is the first case of neuro-Sweet disease treated with rituximab,

tocilizumab, and mycophenolate mofetil. Tocilizumab, which is commonly used in rheumatoid arthritis, is reportedly associated with neutropenia in some cases [15]. Although the exact mechanism is not established, this anti-neutrophil effect may serve as a therapeutic target in Sweet syndrome [16]. A case of Sweet syndrome or neuro-Sweet disease treated with mycophenolate mofetil has not been reported to date. Although mycophenolate mofetil was initiated after cutaneous relapse in November 2018, the contribution of mycophenolate mofetil cannot be established due to concomitant administration of corticosteroids followed by tocilizumab. However, tentative therapeutic effects of mycophenolate mofetil should be further studied in refractory cases of neuro-Sweet disease. Reversibility of neurologic symptoms even after months from relapse highlights the importance of adequate immunotherapy in steroid-unresponsive neuro-Sweet disease. The mechanism by which each immune-modulating agent acts on neuro-Sweet disease, and priority of each immunotherapy, remain to be elucidated.

## Conflicts of Interest

Jangsup Moon, Soon-Tae Lee, Kyung-Il Park, Sang Kun Lee, Kon Chu have been editorial board of *Encephalitis* since October 2020. They were not involved in the review process of this case report. No other potential conflict of interest relevant to this article was reported.

## Author Contributions

Conceptualization: S Hwang, K Chu; Data curation, Investigation: S Hwang, H Son; Formal analysis, Visualization: S Hwang; Methodology: S Hwang, J Moon, K Chu; Project administration, Resources, Supervision: K Chu; Writing—original draft: S Hwang; Writing—review and editing: all authors.

## References

1. Sweet RD. An acute febrile neutrophilic dermatosis. *Br J Dermatol* 1964;76:349–356.
2. Lim JA, Lee ST, Moon J, et al. Development of the clinical assessment scale in autoimmune encephalitis. *Ann Neurol* 2019;85:352–358.
3. Hisanaga K, Iwasaki Y, Itoyama Y; Neuro-Sweet Disease Study Group. Neuro-Sweet disease: clinical manifestations and criteria for diagnosis. *Neurology* 2005;64:1756–1761.

4. von den Driesch P. Sweet's syndrome (acute febrile neutrophilic dermatosis). *J Am Acad Dermatol* 1994;31:535–556.
5. Hisanaga K, Hosokawa M, Sato N, Mochizuki H, Itoyama Y, Iwasaki Y. "Neuro-sweet disease": benign recurrent encephalitis with neutrophilic dermatosis. *Arch Neurol* 1999;56:1010–1013.
6. Cohen PR. Sweet's syndrome: a comprehensive review of an acute febrile neutrophilic dermatosis. *Orphanet J Rare Dis* 2007;2:34.
7. Leccese P, Alpsy E. Behçet's disease: an overview of etiopathogenesis. *Front Immunol* 2019;10:1067.
8. Schadt CR, Callen JP. Management of neutrophilic dermatoses. *Dermatol Ther* 2012;25:158–172.
9. Kluger N, Gil-Bistes D, Guillot B, Bessis D. Efficacy of anti-interleukin-1 receptor antagonist anakinra (Kineret®) in a case of refractory Sweet's syndrome. *Dermatology* 2011;222:123–127.
10. Seminario-Vidal L, Guerrero C, Sami N. Refractory Sweet's syndrome successfully treated with rituximab. *JAAD Case Rep* 2015;1:123–125.
11. Cook QS, Zdanski CJ, Burkhart CN, Gooze PB, Thompson P, Wu EY. Idiopathic, refractory Sweet's syndrome associated with common variable immunodeficiency: a case report and literature review. *Curr Allergy Asthma Rep* 2019;19:32.
12. Filippi F, Chessa MA, Patrizi A, Baraldi C, Ferrara F, Bardazzi F. Tocilizumab-induced Sweet syndrome in a patient with polymyalgia rheumatica. *Dermatol Pract Concept* 2019;10:e2020019.
13. Drago F, Ciccarese G, Agnoletti AF, Sarocchi E, Parodi A. Neuro sweet syndrome: a systematic review: a rare complication of Sweet syndrome. *Acta Neurol Belg* 2017;117:33–42.
14. Lobo AM, Stacy R, Cestari D, Stone JH, Jakobiec FA, Sobrin L. Optic nerve involvement with panuveitis in Sweet syndrome. *Ocul Immunol Inflamm* 2011;19:167–170.
15. Nakamura I, Omata Y, Naito M, Ito K. Blockade of interleukin 6 signaling induces marked neutropenia in patients with rheumatoid arthritis. *J Rheumatol* 2009;36:459–460.
16. Wright HL, Cross AL, Edwards SW, Moots RJ. Effects of IL-6 and IL-6 blockade on neutrophil function in vitro and in vivo. *Rheumatology (Oxford)* 2014;53:1321–1331.

## Anti-N-methyl-D-aspartate receptor encephalitis 8 years after serial herpes simplex virus type 1 and human herpesvirus type 7 encephalitis

Yoonhyuk Jang\*, Jeong-Min Kim\*, Jangsup Moon, Kyung-Il Park, Soon-Tae Lee, Keun-Hwa Jung, Sang Kun Lee, Kon Chu

*Department of Neurology, Laboratory for Neurotherapeutics, Comprehensive Epilepsy Center, Seoul National University Hospital, Seoul, Korea*

Anti-N-methyl-D-aspartate receptor (NMDAR) encephalitis is triggered by herpesvirus encephalitis. Human herpesvirus type 7 (HHV-7) is a recently described herpesvirus for which neuroinvasion has been reported rarely. We report a case of anti-NMDAR encephalitis detected 8 years after recurrent herpes encephalitis associated with herpes simplex virus type 1 and HHV-7 in an immunocompetent host. Our case suggests that anti-NMDAR encephalitis may be triggered by HHV-7 meningoencephalitis in immunocompetent adults, and patients with a history of herpesvirus encephalitis should be vigilantly monitored.

**Keywords:** Herpes simplex virus 1, Human herpesvirus 7, Encephalitis, Foscarnet, Anti-N-methyl-D-aspartate receptor encephalitis

### Introduction

Anti-N-methyl-D-aspartate receptor (NMDAR) encephalitis is the most common disease among autoimmune encephalitis. Most patients are female, and ovarian teratoma is a source of autoantibody among 40% of patients [1]. However, for male and female patients without teratoma, the mechanism of breakdown of immune tolerance to NMDAR is unclear. It has been suggested that direct damage to the central nervous system (CNS) through viral infection could be the origin of the autoantigen, and previous studies have shown that herpesvirus infection can precede anti-NMDAR encephalitis [2-4].

Herpesviruses are large, double-stranded DNA viruses, of which eight human herpesviruses have been identified [5]. They are mostly neurotrophic, sometimes causing serious neurological manifestations either by primary infection or secondary activa-

tion [5]. Human herpesvirus type 7 (HHV-7) is a recently described herpesvirus that is ubiquitous and mostly acquired in childhood [6]. Primary infection usually occurs in infants, and symptoms vary from a nonspecific high fever to exanthem subitum [6]. Very little is known of HHV-7 infection in the CNS of immunocompetent hosts, but there have been a few case reports describing HHV-7 neuroinvasion [7-9].

Here, we describe a 32-year-old man who developed anti-NMDAR encephalitis after recurrent herpesvirus meningoencephalitis. Written informed consent was obtained for publication of this case report and accompanying images.

### Case Report

#### Event 1. Herpes simplex virus type 1 encephalitis

A 32-year-old man was admitted due to fever, headache, and al-

Received: November 23, 2020 Revised: December 1, 2020 Accepted: December 2, 2020

Correspondence: Kon Chu

Department of Neurology, Seoul National University Hospital, 101 Daehak-ro, Jongno-gu, Seoul 03080, Korea

E-mail: stemcell.snu@gmail.com

ORCID: <https://orcid.org/0000-0001-5863-0302>

\*These authors contributed equally to this work as co-first authors.

Copyright © 2021 by The Korean Encephalitis and Neuroinflammation Society

This is an open access article distributed under the terms of the Creative Commons Attribution Non-Commercial License (<http://creativecommons.org/licenses/by-nc/4.0/>) which permits unrestricted non-commercial use, distribution, and reproduction in any medium, provided the original work is properly cited.

tered mental status. He was previously healthy and had no recent history of travel. A cerebrospinal fluid (CSF) study revealed pleocytosis showing 68/mm<sup>3</sup> of white blood cells with lymphocyte dominance (75%) and mildly elevated protein (58 mg/dL) (Table 1). Brain magnetic resonance imaging (MRI) showed bilateral asymmetric hyperintense lesions on T2-weighted images, with a mass effect involving both insulas, the hippocampus, lingual gyrus, and left anterior temporal area. A polymerase chain reaction (PCR) study was performed for herpes simplex virus type 1 (HSV-1) and HSV-2 in the CSF specimen and revealed a positive result for HSV-1 DNA. No other viral gene studies were performed. The patient was diagnosed with HSV-1 encephalitis and received acyclovir at a dose of 500 mg intravenous (IV) every 8 hours. After 20 days of treatment, he was discharged without symptoms.

**Event 2. HHV-7 encephalitis**

One month after discharge, the patient complained of visual hallucination and agitation and showed aggressive behavior. He was readmitted to the hospital, and a CSF study disclosed 18/mm<sup>3</sup> of white blood cells (Table 1), with HSV-1 DNA detected by PCR. He received acyclovir 500 mg IV every 8 hours for 1 month, but his symptoms worsened to drowsy mental status with no response to verbal stimuli and intermittent oral automatism. Body temperature was high at 37.6°C. The follow-up CSF study showed 14/mm<sup>3</sup> of white blood cells, no red blood cells, 25 mg/dL of protein, and 77 mg/dL of glucose (serum glucose, 97 mg/dL) (Table 1). Video-electroencephalogram (EEG) monitoring detected intermittent semirhythmic delta waves in the right temporal area. Brain MRI showed increased extent of the T2 hyperintense lesion, which was more prominent at the left side, at

the bilateral temporal lobes, and positron emission tomography revealed profound hypometabolism in the left temporal lobe (Figure 1A and C). Viral gene PCR was used to evaluate HSV-1, HSV-2, varicella-zoster virus, Epstein-Barr virus, cytomegalovirus, HHV-6, and HHV-7. All tests were negative except that for HHV-7 DNA, which was strongly positive in the CSF specimen. Thus, the patient received foscarnet of 2,000 mg IV every 8 hours for HHV-7 encephalitis. After 2 weeks of treatment, he recovered from the drowsy mental state and no longer showed oral automatism or aggressive behavior. Brain MRI showed clear improvement (Figure 1B), and follow-up EEG indicated resolution of the intermittent rhythmic delta slowing in the right temporal area. He was discharged with mild short-term memory decline with instruction to maintain oxcarbazepine of 1,200 mg/day and levetiracetam of 1,000 mg/day.

**Event 3. Anti-NMDAR encephalitis**

The patient had no symptom recurrence, even after tapering of the antiepileptic drug oxcarbazepine to 900 mg/day. Eight years later, however, seizure recurred with severe headache and auditory hallucinations. Thorough evaluation was repeated, including viral gene PCR and autoantibody tests. All viral gene PCR evaluations were negative, but anti-NMDAR antibody was detected in serum (Table 1). Immunotherapy with IV immunoglobulin and rituximab was planned for the patient. After four cycles of rituximab treatment, his symptoms improved, and he has had no seizure during four years of follow-up.

**Polymerase chain reaction**

Nucleic acid was prepared from cell pellets of CSF or peripheral blood mononuclear cells using the QIAamp DNA Blood Mini Kit (Qiagen, Crawley, UK) following the manufacturer’s instruc-

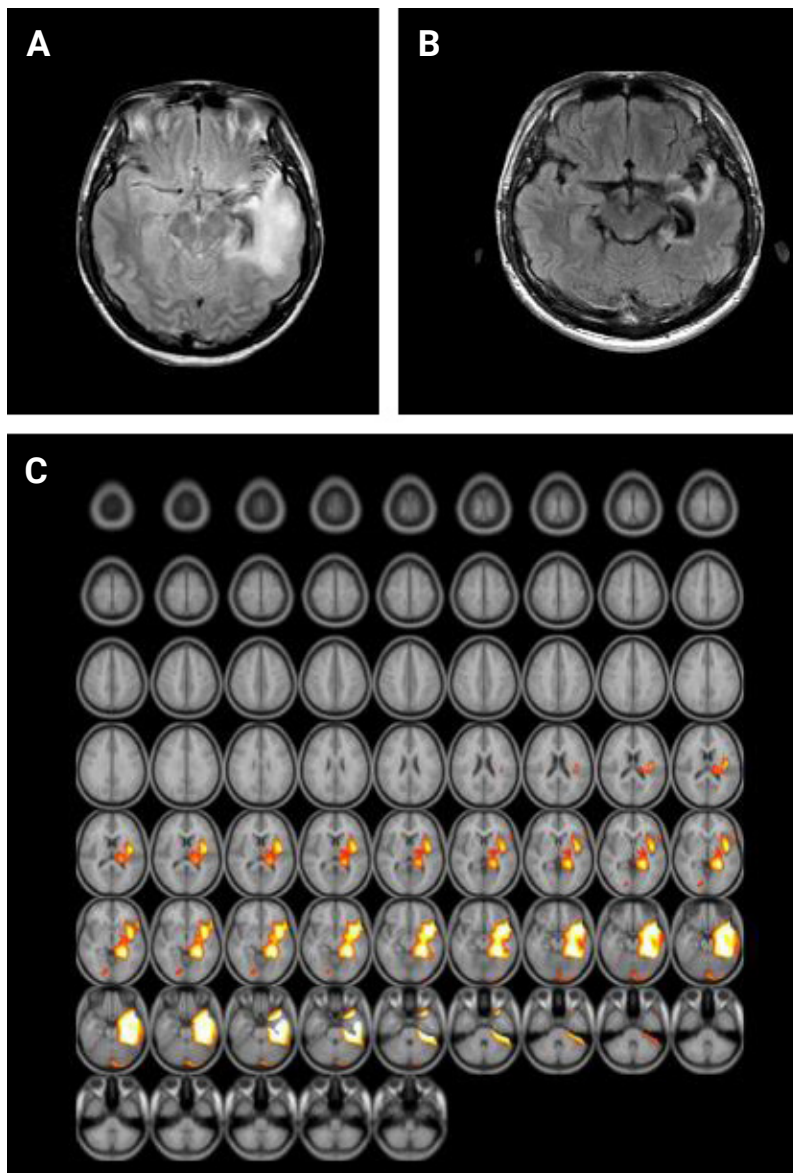
**Table 1** Cerebrospinal fluid profiles

	Day 1	Day 44	Day 84	Eight years later
<b>Status</b>	Initial manifestation	Relapse	Aggravation	Relapse
<b>Symptom</b>	Headache, fever, drowsy mentality	Abnormal behavior, visual hallucination	Drowsy mentality	Seizure, headache, auditory hallucinations
<b>CSF study</b>				
<b>RBC (/μL)</b>	4	1,020 <sup>b)</sup>	0	NA
<b>WBC (/μL)</b>	68	18	14	NA
<b>Protein (mg/dL)</b>	58	52	25	NA
<b>Glucose (mg/dL)</b>	60	62	77	NA
<b>PCR<sup>a)</sup></b>	HSV-1(+)	HSV-1(+)	HSV-1(-), HHV-7(+)	HSV-1(-), HHV-7(-)
<b>Autoantibody</b>	NA	NA	NA	Anti-NMDAR antibody (+)
<b>Treatment</b>	Acyclovir 500 mg	Acyclovir 500 mg	Foscarnet	Rituximab
<b>Response</b>	Recovered	No response	Recovered	Recovered

CSF, cerebrospinal fluid; RBC, red blood cell; WBC, white blood cell; PCR, polymerase chain reaction; HSV-1, herpes simplex virus type 1; HHV-7, human herpesvirus type 7; NA, not available.

<sup>a)</sup>Only HSV-1 and 2 DNA were examined in the first two lumbar puncture studies.

<sup>b)</sup>Note that traumatic tap was performed in a lumbar puncture study performed on day 44.

**Figure 1** Brain images of human herpesvirus type 7 encephalitis

**(A)** Fluid-attenuated inversion recovery shows high signal intensity, more prominent on the left side, at the bilateral temporal lobes. **(B)** The lesions regressed after foscarnet treatment. **(C)** Positron emission tomography with statistical parametric mapping analysis reveals profound hypometabolism in the left temporal lobe.

tions. We performed nested PCR using 15 L of nucleic acid from serum or CSF. The sequences of the outer pair of primers were TAT CCC AGC TGT TTT CAT ATA GTA AC and GCC TTG CGG TAG CAC TAG ATT TTT TG, and the sequences of the inner pair of primers were CAG AAA TGA TAG ACA GAT GTT GG and TAG ATT TTT TGA AAA AGA TTT AAT AAC. The PCR products were compared by electrophoresis on 2.5% agarose gels containing ethidium bromide. Positive results were confirmed by repeated tests.

### Antibody determination

Anti-NMDAR antibody was confirmed with two methods, as described previously [10]. These methods were serum and CSF assays with immunostaining of rat brain sections and a cell-based immunochemistry kit (Euroimmun AG, Lübeck, Germany). Antibodies against the contactin-associated protein-like 2 (CASPR2), the leucine-rich glioma-inactivated 1 (CASPR2) receptor, anti- $\alpha$ -amino-3-hydroxy-5-methyl-4isoxazolepropionic acid 1 (AMPA1), AMPA2, and  $\gamma$ -aminobuty-

ic-acid type B (GABA-B) receptors were negative, as were antibodies against Hu, Yo, Ri, Ma2, CV2, amphiphysin, recoverin, Sox1, and titin antibodies.

## Discussion

Our case illustrates recurrent meningoencephalitis associated with HSV-1, HHV-7, and subsequent anti-NMDAR encephalitis in an immunocompetent adult host. After HHV-7 had been treated with foscarnet, the patient's drowsy mental state significantly improved, along with cessation of nonconvulsive seizures. Follow-up brain MRI and EEG showed findings consistent with resolution of encephalitis, including absence of active lesions and epileptic activity, respectively. The seizure relapse 8 years later led to detection of anti-NMDAR encephalitis, and the patient was treated with immunotherapy.

In the present case, HHV-7 could be associated with recurrent encephalitis after the first HSV-1 infection had been sufficiently treated by acyclovir. The causative agent for the initial event could have been HSV-1, considering the bilateral temporal lobar involvement demonstrated on brain MRI and detection of HSV-1 DNA by PCR. Recurrent encephalitis in HSV-1 infection is occasionally reported and is related with severity of the first infection [5]. Because the initial viral DNA studies examined only HSV-1 and HSV-2, it is unclear whether HHV-7 initially coinfecting the patient or if he was infected later. Nonetheless, a later CSF study revealed a negative result for HSV-1 DNA and a positive result for HHV-7 DNA, suggesting involvement of HHV-7 infection in the second episode of encephalitis.

Furthermore, dramatic symptom relief after foscarnet treatment supports the idea that HHV-7 was related to the recurrent encephalitis in our case. Although there are no treatment guidelines or randomized clinical trials for HHV-7 infection, foscarnet or ganciclovir is recommended as a therapeutic option because HHV-7 is resistant to acyclovir [7]. On the other hand, acyclovir, which must be phosphorylated by virus-encoded kinases to retain antiviral activity, is an effective antiviral agent against HSV-1 and HSV-2 [11]. Foscarnet and its analogues achieve their antiviral effects via inhibition of viral polymerases, without activation or phosphorylation of the compounds by viral or cellular proteins [12]. Therefore, they have shown effective antiviral activity against acyclovir-resistant herpes simplex infection and herpesviruses such as HHV-7 [11,13].

In the present case, the autoimmune encephalitis was identified 8 years after serial herpesvirus encephalitis, and the symptoms might have been too mild to be detected before the infection

was identified. Whether the NMDAR antibody was present at the time of HHV-7 infection is unclear; NMDAR-autoantibody detection was not available in 2007 when there was no concept of anti-NMDAR encephalitis [14]. Moreover, we do not know whether HSV-1 infection or HHV-7 infection resulted in breakdown of immune tolerance to NMDAR. According to the hypothesis that CNS damage triggers autoimmunity by exposure of NMDARs [4], either herpesviruses could be the cause of the patient's anti-NMDAR encephalitis. Our result implies that HHV-7 infection, which is ubiquitous and generally asymptomatic, can be the origin of autoimmunity for patients with anti-NMDAR encephalitis who have no teratoma. Thus, development of anti-NMDAR encephalitis should be vigilantly monitored in patients with a history of herpes virus encephalitis. Conversely, in patients with anti-NMDAR encephalitis who have no teratoma, herpes viral infection history should be carefully investigated.

In summary, we report a case of recurrent herpesvirus encephalitis followed by anti-NMDAR encephalitis in an immunocompetent young man. This report furthers our knowledge about the clinical manifestations of rare HHV-7 infection and suggests that anti-NMDAR encephalitis can be identified years after herpes virus infection.

## Conflicts of Interest

Jangsup Moon, Kyung-Il Park, Soon-Tae Lee, Keun-Hwa Jung, Sang Kun Lee, Kon Chu have been editorial board of *Encephalitis* since October 2020. They were not involved in the review process of this case report. No other potential conflict of interest relevant to this article was reported.

## Author Contributions

Conceptualization: Chu K; Investigation: Kim JM, Moon J, Chu K; Data curation: Jang Y, Kim JM; Formal analysis: Lee ST; Resources, Funding acquisition: Park KI, Jung KH, Chu K, Lee SK; Supervision: Chu K; Writing—original draft: Jang Y, KimJM; Writing—review and editing: all authors.

## Acknowledgements

This work was supported by the Ministry of Health and Welfare (grant No. A060452), Republic of Korea.



## References

1. Dalmau J, Graus F. Antibody-mediated encephalitis. *N Engl J Med* 2018;378:840–851.
2. Leypoldt F, Titulaer MJ, Aguilar E, et al. Herpes simplex virus-1 encephalitis can trigger anti-NMDA receptor encephalitis: case report. *Neurology* 2013;81:1637–1639.
3. Salovin A, Glanzman J, Roslin K, Armangue T, Lynch DR, Panzer JA. Anti-NMDA receptor encephalitis and nonencephalitic HSV-1 infection. *Neurol Neuroimmunol Neuroinflamm* 2018;5:e458.
4. Armangue T, Leypoldt F, Málaga I, et al. Herpes simplex virus encephalitis is a trigger of brain autoimmunity. *Ann Neurol* 2014;75:317–323.
5. Gilden DH, Mahalingam R, Cohrs RJ, Tyler KL. Herpesvirus infections of the nervous system. *Nat Clin Pract Neurol* 2007;3:82–94.
6. Levy JA. Three new human herpesviruses (HHV6, 7, and 8). *Lancet* 1997;349:558–563.
7. van den Berg JS, van Zeijl JH, Rottevel JJ, Melchers WJ, Gabreëls FJ, Galama JM. Neuroinvasion by human herpesvirus type 7 in a case of exanthem subitum with severe neurologic manifestations. *Neurology* 1999;52:1077–1079.
8. Ward KN, Kalima P, MacLeod KM, Riordan T. Neuroinvasion during delayed primary HHV-7 infection in an immunocompetent adult with encephalitis and flaccid paralysis. *J Med Virol* 2002;67:538–541.
9. Mihara T, Mutoh T, Yoshikawa T, Yano S, Asano Y, Yamamoto H. Post-infectious myeloradiculoneuropathy with cranial nerve involvements associated with human herpesvirus 7 infection. *Arch Neurol* 2005;62:1755–1757.
10. Lee WJ, Lee ST, Byun JI, et al. Rituximab treatment for autoimmune limbic encephalitis in an institutional cohort. *Neurology* 2016;86:1683–1691.
11. De Clercq E, Naesens L, De Bolle L, Schols D, Zhang Y, Neyts J. Antiviral agents active against human herpesviruses HHV-6, HHV-7 and HHV-8. *Rev Med Virol* 2001;11:381–395.
12. Crumacker CS. Mechanism of action of foscarnet against viral polymerases. *Am J Med* 1992;92:3S–7S.
13. Dewhurst S. Human herpesvirus type 6 and human herpesvirus type 7 infections of the central nervous system. *Herpes* 2004;11 Suppl 2: 105A–111A.
14. Dalmau J, Gleichman AJ, Hughes EG, et al. Anti-NMDA-receptor encephalitis: case series and analysis of the effects of antibodies. *Lancet Neurol* 2008;7:1091–1098.

### CONTACT INFORMATION

*encephalitis* Editorial Office

101 Daehak-ro, Jongno-gu, Seoul 03080, South Korea

Tel: +82-2-2072-0629, Fax: +82-2-765-7920

E-mail: editor@encephalitisjournal.org

Editor-in-Chief: Kyung-Il Park, MD, PhD

Department of Neurology, Seoul National University Hospital,  
101 Daehak-ro, Jongno-gu, Seoul 03080, South Korea

### GENERAL INFORMATION

*encephalitis* is the official journal of Korean Encephalitis and Neuroinflammation Society. Published quarterly on the 10th of every January, April, July, and October, the journal reports basic and clinical investigations related to encephalitis and neuroinflammation, publishing original research articles, review/mini-review articles, and clinical studies/case reports, perspectives, and letters to the editor. To submit a manuscript to the *encephalitis*, it is advised to first carefully read the aims and scope section of this journal, as it provides information on the editorial policy and the category of the papers that it accepts from authors. Manuscripts should be prepared for submission to *encephalitis* according to the following instructions. *encephalitis* follows Recommendations for the Conduct, Reporting, Editing, and Publication of Scholarly Work in Medical Journals (<https://www.icmje.org/icmje-recommendations.pdf>) from the International Committee of Medical Journal Editors (ICMJE) if not otherwise described below. Authors will be asked to confirm their compliance with the journal's policies and guidelines during manuscript submission on the web page, and each author will be asked to submit a signed "Authorship Responsibility, Conflicts of Interest, and Copyright Transfer/Publishing Agreement" (available at Instructions & Forms at <http://encephalitisjournal.org/authors/authors.php>) prior to acceptance of their manuscript.

### PUBLICATION AND RESEARCH ETHICS

The journal adheres to the ethical guidelines for research and publication described in the Guidelines on Good Publication (<http://publicationethics.org/resources/guidelines>) and the

Good Publication Practice Guidelines for Medical Journals ([https://www.kamje.or.kr/board/view?b\\_name=bo\\_publication&bo\\_id=13](https://www.kamje.or.kr/board/view?b_name=bo_publication&bo_id=13)).

### Statement of Human and Animal Rights and Informed Consent

Any investigations involving humans and animals should be approved by the Institutional Review Board and Animal Care Committee, respectively, of the institution where the study took place. *encephalitis* will not consider any studies involving humans or animals without the appropriate approval. Informed consent should be obtained, unless waived by the institutional review board, from patients who participated in clinical investigations. Human subjects should not be identifiable, such that patients' names, initials, hospital numbers, dates of birth, or other protected healthcare information should not be disclosed. If experiments involve animals, the research should be based on national or institutional guidelines for animal care and use. *encephalitis* can request an approval by the institutional review board or animal care committee for the other types of articles when necessary. For policies on any issues of research and publication ethics not stated in these instructions, the Guidelines on Good Publication (<http://publicationethics.org/resources/guidelines>) should be applied. The content of each article is the responsibility of the authors and not of *encephalitis*.

### Authorship and Author's Responsibility

The corresponding author takes primary responsibility for communication with the journal during the manuscript submission, peer review, and publication process, and typically ensures that all the journal's administrative requirements, such as providing details of authorship, ethics committee approval, clinical trial registration documentation, and gathering conflict of interest forms and statements, are properly completed, although these duties may be delegated to one or more coauthors. The corresponding author should be available throughout the submission and peer review process to respond to editorial queries in a timely way, and should be available after publication to respond to critiques of the work and cooperate with any requests from the journal for data or additional information should questions about the paper arise after publication. Authors are responsible for the whole content of each article. Co-authorship should be

based on the following 4 criteria:

- Substantial contributions to the conception or design of the work; or the acquisition, analysis, or interpretation of data for the work; AND
- Drafting the work or revising it critically for important intellectual content; AND
- Final approval of the version to be published; AND
- Agreement to be accountable for all aspects of the work in ensuring that questions related to the accuracy or integrity of any part of the work are appropriately investigated and resolved.

If any persons who do not meet above 4 criteria, they may be listed as contributors in Acknowledgments section. There is no limit to the number of authors, and in principle, only one author should contact the editorial board. In the case of multi-center or multi-disciplinary research, up to two corresponding authors are allowed. *encephalitis* does not allow adding authors or changing the first or the corresponding authors once its decision of 'Accept as it is' is made. If any author wishes to be removed from the byline, he or she should submit a letter signed by the author, as well as all other authors, indicating his or her wish to be deleted from the list of authors. Any change in the name order in the byline requires a letter signed by all authors indicating agreement with the same.

### Conflict of Interest

The authors should disclose all potential conflicts of interest including any research funding, other financial support, and material support for the work. The corresponding author must inform the editor of any potential conflicts of interest that could influence the authors' interpretation of the data. If there is a disclosure, the editors, reviewers, and reader can approach the manuscripts after understanding the situation.

### Originality and Duplicate Publication

Manuscripts under review or published by other journals will not be accepted for publication in *encephalitis*, and articles published in this journal are not allowed to be reproduced in whole or in part in any type of publication without permission of the Editorial Board. Figures and tables can be used freely if original source is verified according to Creative Commons Non-Commercial License. It is mandatory for all authors to resolve any copyright issues when citing a figure or table from a different journal that is not open access. Regarding duplicate publication, plagiarism, and other problems related to publication ethics, "Good Publication Practice Guidelines for Medical Journals"

([https://www.kamje.or.kr/board/view?b\\_name=bo\\_publication&bo\\_id=7](https://www.kamje.or.kr/board/view?b_name=bo_publication&bo_id=7)) should be followed.

### Secondary Publication

It is possible to republish manuscripts if the manuscripts satisfy the conditions of acceptable secondary publication of the *Recommendations* by ICMJE (available from: <http://www.icmje.org/recommendations/browse/publishing-and-editorial-issues/overlapping-publications.html#three>) as followings: Certain types of articles, such as guidelines produced by governmental agencies and professional organizations, may need to reach the widest possible audience. In such instances, editors sometimes deliberately publish material that is also being published in other journals, with the agreement of the authors and the editors of those journals. Secondary publication for various other reasons, in the same or another language, especially in other countries, is justifiable and can be beneficial provided that the following conditions are met. (1) The authors have received approval from the editors of both journals (the editor concerned with secondary publication must have access to the primary version). (2) The priority of the primary publication is respected by a publication interval negotiated by both editors with the authors. (3) The paper for secondary publication is intended for a different group of readers; an abbreviated version could be sufficient. (4) The secondary version faithfully reflects the authors, data, and interpretations of the primary version. (5) The secondary version informs readers, peers, and documenting agencies that the paper has been published in whole or in part elsewhere—for example, with a note that might read, "This article is based on a study first reported in the [journal title, with full reference]"—and the secondary version cites the primary reference. (6) The title of the secondary publication should indicate that it is a secondary publication (complete or abridged republication or translation) of a primary publication.

### Process to Manage the Research and Publication Misconduct

When the Journal faces suspected cases of research and publication misconduct such as redundant (duplicate) publication, plagiarism, fraudulent or fabricated data, changes in authorship, undisclosed conflict of interest, ethical problem with a submitted manuscript, a reviewer who has appropriated an author's idea or data, complaints against editors, and etc., The resolving process will be followed by flowchart provided by the COPE (<http://publicationethics.org/resources/flowcharts>). The discussion and decision on the suspected cases are done by Editorial Board.

## Registration of Clinical Trial Research

Any research that deals with a clinical trial should be registered with a primary national clinical trial registration site such as Korea Clinical Research Information Service (CRiS, <https://cris.nih.go.kr>), other primary national registry sites accredited by World Health Organization (<https://www.who.int/ictrp/network/primary/en/>) or ClinicalTrials.gov (<https://clinicaltrials.gov>), a service of the US National Institutes of Health.

## Data Sharing Statement

*encephalitis* accepts the ICMJE *Recommendations* for data sharing statement policy (<http://icmje.org/icmje-recommendations.pdf>). Authors may refer to the editorial, "Data Sharing statements for Clinical Trials: A Requirement of the International Committee of Medical Journal Editors," in JKMS vol. 32, no. 7:1051-1053 (<https://doi.org/10.3346/jkms.2017.32.7.1051>).

## Editorial Responsibilities

Editorial board will continuously work for monitoring/safeguarding publication ethics: guidelines for retracting articles; maintenance of the integrity of the academic record; preclusion of business needs from compromising intellectual and ethical standard; publishing corrections, clarifications, retractions and apologies when needed; no plagiarism, no fraudulent data. Editors are always keeping following responsibilities: responsibility and authority to reject/ accept article; no conflict of interest respect to articles they reject/ accept; acceptance of a paper when reasonably certain; promoting publication of correction or retraction when errors are found; preservation of anonymity of reviewers.

## COPYRIGHTS, OPEN ACCESS, OPEN DATA, ARCHIVING, AND DEPOSIT POLICY

### Copyrights

The manuscript, when published, will become the property of the journal. Copyrights of all published materials are owned by the Korean Society of Encephalitis and Neuroinflammation. All authors must sign the Transfer of Copyright Agreement when they submit their manuscript. This form is available at our website.

### Open Access Policy

*encephalitis* is an Open Access journal distributed under the terms of the Creative Commons Attribution Non-Commercial License (<https://creativecommons.org/licenses/by-nc/4.0/>) which permits unrestricted non-commercial use, distribution,

and reproduction in any medium, provided the original work is properly cited. Author(s) do not need to be permitted for use of tables or figures published in *encephalitis* in other journals, books, or media for scholarly and educational purposes. This is in accordance with the Budapest Open Access Initiative definition of open access. It also follows the open access policy of PubMed Central at the United States National Library of Medicine (NLM) (<https://www.ncbi.nlm.nih.gov/pmc/>).

## Open data policy

For clarification on result accuracy and reproducibility of the results, raw data or analysis data will be deposited to a public repository or *encephalitis* homepage after acceptance of the manuscript. If the data is already a public one, its URL site or sources should be disclosed. If data cannot be publicized, it can be negotiated with the editor. If there are any inquiries on depositing data, authors should contact the Editorial Office for more information.

## Archiving Policy

According to the deposit policy (self-archiving policy) of Sherpa/ Romeo (<http://www.sherpa.ac.uk>), authors can archive preprint (i.e., pre-refereeing) or postprint (i.e., final draft post-refereeing). Authors can archive publisher's version/PDF.

## GUIDELINES FOR MANUSCRIPT FORMATTING

### 1. General Guidelines

- The manuscript must be written in English.
- The manuscript should be organized in a single file, which starts with the title page, abstract and keywords, introduction, materials and methods, results, discussion, acknowledgments, statements on conflicts of interest, references, tables, and figure legends.
- All text files should be in Microsoft Word format (DOC or DOCX) and all figures need to be in JPG/JPEG format. Text or figure files should not be uploaded as PDF files.
- The manuscript should use an 11- or 12-point font size and be double spaced on 21.0 cm × 29.7 cm (A4) paper with 3.0 cm margins at the top, bottom, and left margin. Left-aligned text should be used.
- The authors should not number the pages or the lines. The page and line numbers will automatically be generated when the uploaded manuscript is converted to PDF format.
- Use only standard abbreviations; use of nonstandard abbreviations can be confusing to readers. Avoid abbreviations in the

title of the manuscript. The spelled-out abbreviation followed by the abbreviation in parentheses should be used on first mention.

- When quoting from other sources, give a reference number after the author's name or at the end of the quotation.
- Authors should express all measurements in conventional units, using the International System (SI) of units.

- Biological names of organisms:

- Saccharomyces cerevisiae*, *E. coli*

- Restriction enzymes and some enzymes:

- EcoRI*, *Taq polymerase*

- Names of genes: *Src*, *C-H-ras*, *Myc*

- Latin words: *in vivo*, *in vitro*, *in situ*

- Centrifugation force: 100,000 × *g*

- The names and locations (city and state/province or country) of the manufacturers of equipment and generic names should be given.
- For specific study designs, such as randomized control studies, studies of diagnostic accuracy, meta-analyses, observational studies, and nonrandomized studies, authors are encouraged to also consult the reporting guidelines relevant to their specific research design. A good source of reporting guidelines is the EQUATOR Network (<https://www.equator-network.org>) and the NLM ([https://www.nlm.nih.gov/services/research\\_report\\_guide.html](https://www.nlm.nih.gov/services/research_report_guide.html)).
- Please also refer to the most recent articles published in *encephalitis* for style.

## 2. Main Document

- The main document should contain the following components in a single Microsoft Word file, each component starting on a separate page: title page, abstract, main body, acknowledgments/statements on conflicts of interest, references, and figure legends.

### 2.1. Title Page

- Include the following items on the title page:
  - Title
  - Abbreviated title
  - Names, affiliations, and addresses of all authors
  - Contact information of the corresponding author
  - Type of manuscript
- Each author's full name, not initials, must be provided in the order of first name, middle name (if it exists), and last name for all participating authors, e.g., John (first name) Doe (last name).

- The abbreviated title will be printed at the top of each page of the published paper and should be within 10 words.
- When authors from different institutions/addresses are included, the authors should be matched with their organizations by placing the relevant organization number in superscript after each author's name.
- The contact information of the corresponding author should include the mailing address and e-mail address.
- ORCID: Open researcher and contributor ID (ORCID) of all authors are recommended to be provided. To have ORCID, authors should register in the ORCID web site available from: <https://orcid.org>. Registration is free to every researcher in the world.

### 2.2. Abstract

- Reference citations should not be used in the abstract. Abbreviations should be minimized and, if used, must be defined within the abstract by the full term followed by its abbreviation in parentheses.
- The abstract should be concise, less than 250 words, and describe the subject of research concisely, in a paragraph. The abstract for an original article must be structured to include a Purpose, Methods, Results, and Conclusion as follows:
  - Purpose:** In one or two sentences, the specific purpose of the article and why it is worthy of attention should be indicated. The purpose stated here should be identical to the one given in the title of the paper and the introduction.
  - Methods:** The methods used to achieve the purpose explained in the first paragraph should be described succinctly, stating what was done and how bias was controlled, what data were collected, and how the data were analyzed.
  - Results:** The findings of the methods described in the preceding paragraph are to be presented here, with specific data. All results should flow logically from the methods described.
  - Conclusion:** In one or two sentences, the conclusion of the study should be stated. This should relate directly to the purpose of the paper, as defined in the first paragraph of the abstract.
- Unlike that for an Original Article, the abstract for review/mini-review/case report consist of a single paragraph without separate sections. The most recently published articles should be consulted for style.
- Three to five keywords (index terms) should appear after the abstract. For the selection of keywords, refer to the list of Medical Subject Headings (MeSH, <http://www.ncbi.nlm.nih.gov/mesh>).

## 2.3. Main Body

### 2.3.1. Original Article

Original articles are papers containing results of basic and clinical investigations, which are sufficiently well documented to be acceptable to critical readers. The maximum length of a manuscript is 5,000 words (exclusive of the title page and abstract), 50 references (if the references exceed 50, authors can consult with the Editorial Office). A total of 8 figures or tables are allowed; additional tables and figures may be provided using the online data supplement system

#### *Introduction*

The introduction provides the research background and specific purpose or objectives, generally enough to inform the readers of the topic, and relevant findings of others are described. The hypothesis tested can be stated. The references should be as few and pertinent as possible.

#### *Materials and Methods*

- The first paragraph should address whether the study was conducted under an approval by the institutional review board (with or without patient informed consent) and animal care committee of the institution where the study took place for any investigation involving humans and animals, respectively.
- The materials (or subjects), inclusion and exclusion criteria, research plan, and the methods used should all be described.
- Ensure correct use of the terms sex (when reporting biological factors) and gender (identity, psychosocial or cultural factors), and, unless inappropriate, report the sex and/or gender of study participants, the sex of animals or cells, and describe the methods used to determine sex and gender. If the study was done involving an exclusive population, for example in only one sex, authors should justify why, except in obvious cases (e.g., prostate cancer). Authors should define how they determined race or ethnicity and justify their relevance.
- How the disease was confirmed and how subjectivity in observations was controlled should be explained in detail, if relevant.
- When experimental methodology is the main issue of the paper, the experimental process should be described in detail so as to make it possible for the reader to recreate the experiment as closely as possible.
- The methods of statistical analysis and criteria for statistical significance should be described.
- If the study includes reuse/overlap of materials previously published or under consideration for publication elsewhere, the reuse/overlap of study materials should be clearly stated.

#### *Results*

- The results of the paper should be described logically according to the Methods section.
- Tables and figures are recommended when they can present data more succinctly and clearly. Do not duplicate the content of tables or figures in the Results section.
- Briefly describe the core results related to the conclusion in the text when data are provided in tables or in figures.
- In the Results section, audio or video files are also welcomed. Supplementary results can be placed in the Appendix

#### *Discussion*

- In the first part of the discussion, the main findings should be briefly summarized, then possible explanations for these findings should be explored, and these results should be compared and contrasted with the findings of other relevant studies.
- The results of previous relevant studies should not be mentioned repeatedly, but any concordance or discordance should be noted.
- The core findings and the conclusions derived from them should be emphasized according to the best available evidence.
- In the last part of the discussion, the limitations of the study, future research suggestions or plans, and the conclusion should all be described. If there was a research hypothesis in the introduction section, whether it was supported should be stated.

#### *Conflict of interest*

- State any potential conflict of interest that could influence the authors' interpretation of the data, such as financial support from or connections to pharmaceutical companies, political pressure from interest groups, or academically related issues.

#### *Acknowledgments and Author contribution*

- All persons who have made substantial contributions but have not met the criteria for authorship are acknowledged here. All sources of funding applicable to the study should be explicitly stated here.
- What authors have done for the study should be described in this section. To qualify for authorship, all contributors must meet at least one of the seven core contributions by CRediT (conceptualization, methodology, software, validation, formal analysis, investigation, data creation), as well as at least one of the writing contributions (original draft preparation, review and editing). Contributions will be published with the final article, and they should accurately reflect contributions to the work. The submitting author is responsible for completing this information at submission, and it is expected that all authors

will have reviewed, discussed, and agreed to their individual contributions ahead of this time.

### References

- In the text, references should be cited using Arabic numerals in brackets (e.g., [1], [2,3], [4-6]) and numbered in the order cited.
- In the references section, the references should be numbered and listed in the order of their appearance in the text.
- List all authors when there are six or fewer; for seven or more, list only the first three and add “et al.”
- If an article has been published online but has not yet been given an issue or pages, the digital object identifier (DOI) should be supplied.
- Journal titles should be abbreviated in the style used in Medline.
- Other types of references not described below should follow “Samples of Formatted References for Authors of Journal Articles” ([https://www.nlm.nih.gov/bsd/uniform\\_requirements.html](https://www.nlm.nih.gov/bsd/uniform_requirements.html)).
- Unpublished data should not be cited in the reference list, but parenthetically in the text, for example: (Smith DJ, personal communication), (Smith DJ, unpublished data).
- The style and punctuation for journal articles, books, or book chapters should follow the format illustrated in the following examples:

#### - Journal article

Ahn SJ, Moon J, Sunwoo JS, et al. Respiratory virus-related meningoencephalitis in adults. *encephalitis* 2021;1:14-19.

#### - Journal article published electronically ahead of print

Mantegazza R, Wolfe GI, Muppidi S, et al. Post-intervention status in patients with refractory myasthenia gravis treated with eculizumab during REGAIN and its open-label extension. *Neurology* 2020 Nov 23 [Epub]. <https://doi.org/10.1212/WNL.00000000000011207>.

#### - Conference paper

Mark MH, Dickson DW, Schwarz KO, et al. Familial diffuse Lewy body disease. Presented at the 10th International Symposium on Parkinson's Disease; October 19, 1991; Tokyo.

#### - Forthcoming

Tian D, Araki H, Stahl E, Bergelson J, Kreitman M. Signature of balancing selection in Arabidopsis. *Proc Natl Acad Sci USA*. Forthcoming 2002.

#### - Book

Murray PR, Rosenthal KS, Kobayashi GS, Pfaller MA. *Medical microbiology*, 4th ed. St Louis: Mosby; 2002.

Gilstrap LC 3rd, Cunningham FG, VanDorsten JP, editors. *Operative obstetrics*, 2nd ed. New York: McGraw-Hill; 2002.

Meltzer PS, Kallioniemi A, Trent JM. Chromosome Alterations in Human Solid Tumors. In: Vogelstein B, Kinzler KW, editors. *The Genetic Basis of Human Cancer*. New York: McGraw-Hill; 2002. p. 93-113.

#### - Online book or Web site

Foley KM, Gelband H, editors. Improving palliative care for cancer [Internet]. Washington: National Academy Press; 2001 [cited 2002 Jul 9]. Available from: <https://www.nap.edu/catalog/10149/improving-palliative-care-for-cancer>.

### Tables

- The tables should start on a separate page. The tables should be numbered using Arabic numerals. The title of the table should be clearly stated in the form of a sentence or a paragraph.
- Tables should not be longer than one page and should contain at least four lines and two columns of data.
- Tables are to be numbered in the order in which they are cited in the text.
- Abbreviations should be defined in a footnote below each table.
- Tables should be self-explanatory and readily comprehensible.
- Written permission from the prior publisher should be obtained for the use of all previously published tables and copies of the permission letter should be submitted.
- In case of the use of previously published tables, the original source must be noted in the table footnote, and a statement that copyright permission was granted, if relevant, should be made. All non-standard abbreviations should be explained in the footnotes. Footnotes should be indicated by <sup>a)</sup>, <sup>b)</sup>, <sup>c)</sup>, <sup>d)</sup>, ... Statistical measures such as SD or SE should be identified.

### Figure Legends

- The figure legends should start on a separate page. Legends should be numbered in the order in which they are cited, using Arabic numerals.
- Figure title includes patient age and a diagnosis in a phrase followed by a description using one complete sentence rather than a phrase or paragraph for each figure part.
- For a description regarding the features in the figure, the sentence is described in present tense. For a description regarding the features not appeared in the figure, the sentence is described in past tense.
- For microscopic findings, the staining method and the scale should be included in parenthesis (e.g., H&E stain, × 100).

- In case of the use of previously published figures, the original source must be revealed in the figure legend.

#### *Figures*

- All figure parts related to one patient should have the same figure number and use English letters after the numerals to distinguish each figure part, e.g., Figure 1A, 1B, etc.
- Multiple figures mentioned in the text should be described as follows, e.g., Figures 1, 3.
- Multiple figures within the same figure number mentioned in the text should be described as follows, e.g., Figure 1A, C.
- Each figure part should be sent as a separate image file.
- Labels/arrows should be of professional quality.
- All names and all other identifiers of the patient, authors, and authors' institutions should be removed from the figures.
- After cropping to the area of interest, the images should be at least 300 dpi in resolution and 10-15 cm in width.
- Color figures should be in RGB color mode and line drawings should be black on a white background.
- For initial submission, only the JPG/JPEG format is acceptable. The authors will later be asked to submit TIF/TIFF files without any arrows or other markings for the finally accepted manuscript.
- Written permission from the prior publisher should be obtained for the use of all previously published illustrations and copies of the permission letter should be submitted.
- The authors may wish to make written suggestions about the arrangement of the illustrations

#### *Video clips*

- Video clips can be submitted for placement on the journal website. All videos are subject to peer review and can be uploaded as supplementary materials.
- A video file submitted for consideration for publication should be in complete and final format and at as high a resolution as possible. Any editing of the video will be the responsibility of the author.
- *encephalitis* recommends Quicktime, AVI, MPEG, MP4, or RealMedia file formats of less than 5 minutes duration.
- A legend to accompany the video should be double-spaced in a separate file.
- All copyrights for video files after acceptance of the main article are automatically transferred to *encephalitis*.

#### *Supplementary data*

- Supplementary data: If there are complementary materials that help the understanding of readers or if there is a large amount of data, these may be used as supplementary data.

Supplementary data should be as concise as possible and must be related to the main conclusion of the paper. Supplementary data can include electronic files of high resolution images, background datasets, video materials, animations, and more. Supplementary data will be published online alongside the electronic version of the article. Video data files can be submitted in the same way as a figure or table by referring to the video or animation content. Since video and animation cannot be embedded in the print version, authors have to provide text for both the electronic and the print version for the portions of the article that refer to this content

#### **2.3.2. Review Article**

- A review is generally published as a commissioned paper at the request of the editor(s).
- Review articles contain an Abstract, Introduction, Main text, and Summary (or Conclusion) followed by references, tables, and figure legends.
- A review article is a comprehensive scholarly review on a specific topic. It is not an exhibit of a series of cases.
- Neither new information nor personal opinions are to be included.
- An introduction that explains the scope of the paper is required, and headings should be used appropriately to separate and organize the text.
- Please send us a Presubmission Inquiry before writing a review article. All review articles undergo the same review process as other types of articles prior to acceptance. Reviews have no restrictions on word count or the number of figures and tables. However, authors should eliminate redundancy, emphasize the central message, and provide only the data necessary to convey that message. The approximate length should be less than 5,000 words. There should be an unstructured abstract equal to or less than 250 words. References should not exceed 200 references.
- The most recent Review articles published in *encephalitis* should be consulted for further details on formatting.

#### **2.3.3. Case Reports**

- Case reports will be published only in exceptional circumstances, if they illustrate a rare occurrence of clinical importance. These manuscripts should be organized in the following sequence: title page, abstract and keywords, introduction, case report(s), discussion, acknowledgments, references, tables, figure legends, and figures. Case reports are limited to 2,000 words (excluding the abstract, references, tables, and legends), and references should not exceed 30. A maximum of 5 figures or tables are allowed.



### 2.3.4. Perspective

- A perspective is a report of the authors' viewpoint on a specific subject of interest to our readers as a commissioned paper at the request of the editor(s).
- Little or no new original information is included, and there is limited literature analysis. A perspective is a report of the authors' viewpoint on a specific subject of interest to our readers as a commissioned paper at the request of the editor(s).

### 2.3.5. Letter to the Editor

- Constructive criticism of a specific thesis published by *encephalitis* is welcome.
- Letters to the editor may be in response to a published article or a short, free-standing piece expressing an opinion. If the letters to the editor is in response to a published article, the Editor-in-Chief may choose to invite the article's authors to write a reply. No abstraction is required. The letter should be 1,000 words or less (excluding references and figure legends) with a maximum of 5 references. A maximum of 2 figures including tables is allowed.

### 2.3.6. Editorials

- Editorials are invited by the editor and should be commentaries on articles in the current issue. Editorial topics could include active areas of research, fresh insights, and debates in all fields considered to be of interest to *encephalitis* readers. Editorials should not exceed 1,000 words, excluding references, tables, and figures. References should not exceed 5. A maximum of 3 figures including tables is allowed.

**Table 1. Specification for publication types**

Type of article	Abstract (word)	Text (word) <sup>a)</sup>	Reference	Table & figure
Original article	Structured, 250	5,000	50	8
Review article	250	5,000	200	Not limited
Perspective	Not required	3,000	30	0
Case report	250	2,000	30	5
Letter to the editor	Not required	1,000	5	2
Editorial	Not required	1,000	5	3

## REVIEW PROCESS AND MANUSCRIPT DECISION

- The submitted manuscript will first be evaluated at the editorial office regarding the completeness of the submitted materials and their suitability to *encephalitis*. Modifications/corrections may be requested from the authors at this stage before starting the peer review.
- Submitted manuscripts will generally be reviewed by the editors, as well as two peer reviewers who are experts in the submitted subject matter and the peer reviewers will make sug-

gestions to the editor(s).

- Authors may suggest preferred and non-preferred reviewers during manuscript submission. However, the ultimate selection of the reviewers will be determined by the editor(s).
- The authors can monitor the progress of the manuscript throughout the review process at the submission site (<http://submit.encephalitisjournal.org>).
- Submitted manuscripts will be rendered one of the following decisions:

**Accept:** The manuscript is accepted for publication. Minor Revisions: A revision needs to be submitted within 60 days of the decision. Otherwise, the manuscript will be treated as a new submission.

**Major Revisions:** A revision needs to be submitted within 120 days of the decision. Otherwise, the manuscript will be treated as a new submission.

**Reject, Resubmission allowed:** The authors are allowed to resubmit their work. However, it is effective only when they are able to respond to the various reviewer comments and make substantial changes to the study. The resubmitted manuscript will be treated as a new submission.

**Reject, No further consideration:** The paper will no longer be considered for publication.

- The decision to accept a manuscript is not based solely on the scientific validity and originality of the study content; other factors are considered, including the extent and importance of new information in the paper as compared with that in other papers being considered, the Journal's need to represent a wide range of topics, and the overall suitability for *encephalitis*.
- Decision letters usually, but not always, convey all factors considered for a particular decision. Occasionally, the comments to the authors may appear to be inconsistent with the editorial decision, which takes into consideration reviewers' comments to the editor, as well as the additional factors listed above.
- If the author(s) believe that the journal has rejected their article in error, perhaps because the reviewers have misunderstood its scientific content, an appeal may be submitted by e-mail to the editorial office ([editor@encephalitisjournal.org](mailto:editor@encephalitisjournal.org)). However, appeals are ineffective in most cases and are discouraged.

## ELECTRONIC SUBMISSION OF MANUSCRIPT

### Online Submission

- All manuscripts should be submitted online via the journal's website (<http://submit.encephalitisjournal.org>) by the corre-

sponding author. Once you have logged into your account, the on-line system will lead you through the submission process in a step-by-step orderly process. Submission instructions are available at the website. All articles submitted to the journal must comply with these instructions. Failure to do so will result in the return of the manuscript and, possibly, in delayed publication.

- Author's checklist: You will be first requested to confirm the Author's Checklist. Before submitting the new manuscript, please ensure every point listed in the Author's Checklist has been addressed.
- Document forms: Before you log into the online submission system, it is helpful to prepare the following documents as you will be asked to upload them during the electronic submission process.
  - Author statement forms
  - Cover letter: A Cover Letter must indicate the address, telephone and fax numbers, and E-mail address of the corresponding author.
  - English proof-reading (non-obligatory): Although it is not an obligatory demand, authors may show that their manuscript has been edited through English proofreading

### Submission of Revised Manuscript

- A Major Revision and a Minor Revision should be submitted within 60 days, respectively, of the decisions. Otherwise, the manuscript will be treated as a new submission.
- Please carefully read and follow the instructions written here and those included in the manuscript decision e-mail.
- To start the submission of a revised manuscript, log in at <http://submit.encephalitisjournal.org>. Click the "Manuscripts in Revision" queue in the "My Manuscripts" area. Then, find the submission you wish to start the revision process for and click on the "Create Revision" link for that manuscript.
- To continue with a revised manuscript that has yet to be submitted, click on the "Revised Manuscripts in Draft" queue in the "My Manuscripts" area. Find the submission you wish to continue with and then click on the "Continue Submission" button.
- Please submit a point-by-point response to the editor/reviewer comments by directly pasting it in the box provided in "View and Response to Decision Letter" page as well as by uploading the same as a Microsoft Word document file (DOC/DOCX) on the "File Upload" page
- Any changes in the authorship should be reported to the editor in the cover letter.
- For file uploading, if you have updated a file, please delete the

original version and upload the revised file. To designate the order in which your files appear, use the dropdowns in the "order" column on the "File Upload" page.

- For a revision, we require two copies of the Main Document. Each should be a Microsoft Word document. The FIRST COPY should represent the final "clean" copy of the manuscript. The SECOND "annotated" COPY should have changes tracked using the track changes function in Microsoft Word with marginal memos indicating changes (e.g., E-1 indicates a response to comment #1 of the Editor; R2-3 indicates a response to comment #3 of Reviewer #2).

### AUTHOR CHECKLIST

- Submit manuscripts as DOC or DOCX files. Double space all parts of the manuscript.
- Keep the Abstract, if required, within the word limits (See Table for recommended maximums for articles).
- Include institutional review board approval, informed consent, and/ or animal care committee approval for an Original Article.
- Do not embed figures in the main body or mix figures or tables with the text.
- Digital figures must be at least 300 dpi and a minimum of 10 cm to a maximum of 15 cm in width and height. Use JPG/JPEG formats (for revisions use TIF/TIFF without any arrows or markings).
- Video clips should be less than 5 minutes duration for each.
- Authors will be asked to confirm their compliance with the journal's policies and guidelines during the initial manuscript submission on the web page.
- Verify the accuracy of reference information to enable hyperlinks for the online version of the journal to function properly.
- For previously published materials, send written permission to reprint any figure or any other applicable permissions.
- Provide copies of any material for which there is overlap with your manuscript (see Redundant Publication)

### MANUSCRIPTS ACCEPTED FOR PUBLICATION

#### Final Version

After a paper has been accepted for publication, the names and affiliations of authors should be double-checked, and if the originally submitted image files were of poor resolution, higher resolution image files should be submitted at this time. Symbols (e.g., circles, triangles, squares), letters (e.g., words, abbrevia-

tions), and numbers should be large enough to be legible on reduction to the journal's column widths. All symbols must be defined in the figure caption. If references, tables, or figures are moved, added, or deleted during the revision process, renumber them to reflect such changes so that all tables, references, and figures are cited in numeric order.

### **Manuscript Corrections**

Before publication, the manuscript editor will correct the manuscript such that it meets the standard publication format. The author(s) must respond within 48 hours when the manuscript editor contacts the author for revisions. If the response is delayed, the manuscript's publication may be postponed to the next issue.

### **Proofs**

The corresponding author will receive page proofs for final checking, which should be corrected and returned within 48 hours. The authors must carefully check proofs to see that all er-

rors are corrected and queries from editors answered. Keep a copy for your records.

### **Errata and Corrigenda**

To correct errors in published articles, the corresponding author should contact the journal's Editorial Office with a detailed description of the proposed correction. Corrections that profoundly affect the interpretation or conclusions of the article will be reviewed by the editors. Corrections will be published as corrigenda (corrections of author's errors) or errata (corrections of publisher's errors) in a later issue of the journal.

## **ARTICLE PROCESSING CHARGE**

There is no author's submission fee or other publication-related fee since all costs of the publication process are underwritten by the Korean Encephalitis and Neuroinflammation Society.

- Submit manuscripts as DOC or DOCX files. Double space all parts of the manuscript.
- Keep the Abstract, if required, within the word limits (See Table for recommended maximums for articles).
- Include institutional review board approval, informed consent, and/ or animal care committee approval for an Original Article.
- Do not embed figures in the main body or mix figures or tables with the text.
- Digital figures must be at least 300 dpi and a minimum of 10 cm to a maximum of 15 cm in width and height. Use JPG/JPEG formats (for revisions use TIF/TIFF without any arrows or markings).
- Video clips should be less than 5 minutes duration for each.
- Authors will be asked to confirm their compliance with the journal's policies and guidelines during the initial manuscript submission on the web page.
- Verify the accuracy of reference information to enable hyperlinks for the online version of the journal to function properly.
- For previously published materials, send written permission to reprint any figure or any other applicable permissions.
- Provide copies of any material for which there is overlap with your manuscript (see Redundant Publication)

# Encephalitis Copyright transfer agreement

(Authorship Responsibility and Contributions, Disclosure of Conflicts of Interest, and Copyright Transfer Agreement)

Manuscript Number: \_\_\_\_\_

Manuscript Title: \_\_\_\_\_

Author Name: \_\_\_\_\_

E-mail: \_\_\_\_\_

Corresponding Author Name (Print): \_\_\_\_\_

In order to publish your paper in the encephalitis, all authors must read and sign the statements on

1. Authorship Responsibility; 2. Authorship Contributions; 3. Role of the Funding Source; 4. Disclosure of Conflicts of Interest; and 5. Copyright Transfer Agreement

## 1. Authorship Responsibility

- All authors have seen and approved the content of the submitted manuscript.
- The paper presents original work not previously published in similar form and not currently under consideration by another Journal.
- If the paper contains material (data or information in any other form) that is the intellectual property and copyright of any person(s) other than the Author(s), then permission of the copyright owner(s) to publish that material has been obtained, and is clearly identified and acknowledged in the text of the paper.
- The authors followed ethics guidelines.
- See the Authorship Policy in Instructions for Authors.

## 2. Authorship Contributions

Please indicate the specific contributions made by each author (list the authors' initials, e.g., JKH).

- Conception and design of study: \_\_\_\_\_

- Acquisition of data: \_\_\_\_\_

- Analysis and/or interpretation of data: \_\_\_\_\_

- Drafting the manuscript: \_\_\_\_\_

- Critical revision: \_\_\_\_\_

- Approval of the final version of the submitted manuscript: \_\_\_\_\_

## 3. Role of the Funding Source

Please disclose any funding sources and their role, if any, in the writing of the manuscript or the decision to submit it for publication. The information provided here must match the role of the funding source statement in the manuscript.

#### 4. Disclosure of Conflicts of Interest

Please check A or B

- A. We/I do not have and have not had a financial interest or other relationships in which the individual benefits by receiving a salary, royalty, intellectual property rights, consulting fee, honoraria, ownership interest, or other financial benefit.
- B. We/I now have or have had a financial interest or other relationships in which the individual benefits by receiving a salary, royalty, intellectual property rights, consulting fee, honoraria, ownership interest, or other financial benefit. Please list the manufacturers and/or service providers with whom you have a financial relationship, and describe the condition of your relationship. Please be specific.

---

---

#### 5. Copyright Transfer Agreement

In the occasion of the final acceptance of this manuscript, the authors of the article hereby agree that encephalitis holds the copyright on all materials and the right to publish, transmit, sell and distribute them in the journal or other media. The authors have understood that all proprietary rights other than the copyright (such as patent rights) are maintained by the authors and that for any reproduction of the material published in encephalitis, either in print or online by commercial parties (including publication in other journals or books) prior permission from encephalitis must be acquired.

##### *Corresponding Author*

Signature: \_\_\_\_\_ Date: \_\_\_\_\_

Print name: \_\_\_\_\_

##### *Co-Authors*

Signature: \_\_\_\_\_ Date: \_\_\_\_\_

Print name: \_\_\_\_\_

Signature: \_\_\_\_\_ Date: \_\_\_\_\_

Print name: \_\_\_\_\_

Signature: \_\_\_\_\_ Date: \_\_\_\_\_

Print name: \_\_\_\_\_

Signature: \_\_\_\_\_ Date: \_\_\_\_\_

Print name: \_\_\_\_\_

Signature: \_\_\_\_\_ Date: \_\_\_\_\_

Print name: \_\_\_\_\_

Signature: \_\_\_\_\_ Date: \_\_\_\_\_

Print name: \_\_\_\_\_

Please send the completed and signed form to the Editorial Office by uploading on e-submission site (<http://encephalitisjournal.org>)